
Electronic Thesis and Dissertation Repository

8-20-2013 12:00 AM

Complex Shoulder Instability: The Role of the Latarjet Coracoid Transfer

Ryan Degen, *The University of Western Ontario*

Supervisor: Dr. Jim Johnson, *The University of Western Ontario*

Joint Supervisor: Dr. George Athwal, *The University of Western Ontario*

A thesis submitted in partial fulfillment of the requirements for the Master of Science degree in Medical Biophysics

© Ryan Degen 2013

Follow this and additional works at: <https://ir.lib.uwo.ca/etd>



Part of the [Orthopedics Commons](#), and the [Surgical Procedures, Operative Commons](#)

Recommended Citation

Degen, Ryan, "Complex Shoulder Instability: The Role of the Latarjet Coracoid Transfer" (2013). *Electronic Thesis and Dissertation Repository*. 1454.

<https://ir.lib.uwo.ca/etd/1454>

This Dissertation/Thesis is brought to you for free and open access by Scholarship@Western. It has been accepted for inclusion in Electronic Thesis and Dissertation Repository by an authorized administrator of Scholarship@Western. For more information, please contact wlsadmin@uwo.ca.

COMPLEX SHOULDER INSTABILITY: THE ROLE OF THE LATARJET CORACOID
TRANSFER

Integrated Article Format

by

Ryan Michael Degen

Graduate Program in Medical Biophysics

A thesis submitted in partial fulfillment
of the requirements for the degree of
Master of Science

The School of Graduate and Postdoctoral Studies
The University of Western Ontario
London, Ontario, Canada

© Ryan Michael Degen 2013

Abstract

Recurrent anterior shoulder instability is a common clinical entity that is debilitating for patients, and often requires surgical stabilization. Recurrence rates following soft-tissue stabilization procedures are moderately high and have been attributed to associated bony defects of either the glenoid or humeral head. Complex shoulder instability, which is defined as instability associated with bony defects around the shoulder, is a challenging clinical problem. The Latarjet coracoid transfer has been proposed as a treatment option and its resultant stabilizing effects have been explored in this biomechanical cadaver-based study and compared to alternative procedures.

For both glenoid and humeral head defects, the Latarjet coracoid transfer adequately stabilized the shoulder, outperforming other procedures often clinically utilized for these scenarios. It did, however, result in increased superior translation of the shoulder compared to other procedures, the clinical significance of which is presently unknown.

The Latarjet coracoid transfer is a useful procedure for complex shoulder instability. Further study should assess for any potential deleterious clinical effects following this procedure.

Keywords

Shoulder, Biomechanics, Recurrent instability, Latarjet coracoid transfer

Co-Authorship Statement

- Chapter 1 Ryan Degen – Sole Author
- Chapter 2 Ryan Degen – Study Design, Specimen Preparation, Data Collection, Manuscript Review
- Josh Giles – Study Design, Specimen Preparation, Data Collection, Data Analysis, Manuscript Preparation
- Jim Johnson – Study Design, Manuscript Review
- George Athwal – Study Design, Specimen Preparation, Manuscript Review
- Chapter 3 Ryan Degen – Study Design, Specimen Preparation, Data Collection, Data Analysis, Manuscript Preparation
- Josh Giles – Study Design, Specimen Preparation, Data Collection, Data Analysis, Manuscript Review
- Jim Johnson – Study Design, Manuscript Review
- George Athwal – Study Design, Specimen Preparation, Manuscript Review
- Chapter 4 Ryan Degen – Data Collection, Data Analysis, Manuscript Preparation
- Josh Giles – Study Design, Specimen Preparation, Data Collection, Data Analysis, Manuscript Review
- Harm Boons – Study Design, Specimen Preparation, Manuscript Review
- Jim Johnson – Study Design, Manuscript Review
- George Athwal – Study Design, Specimen Preparation, Manuscript Review
- Chapter 5 Ryan Degen – Sole Author

Publication Status

- Chapter 2 A version of this manuscript has been submitted for publication in the Journal of Bone and Joint Surgery, American Volume and is awaiting review.
- Chapter 3 A version of this manuscript has been submitted for publication in Clinical Orthopaedics and Related Research and is awaiting review.
- Chapter 4 A version of this manuscript has been accepted for publication in the International Journal of Shoulder Surgery. Permission to reprint this version of the manuscript has been granted by the Publisher.

Acknowledgments

I would like to thank a few people who were instrumental in the completion of this thesis. None of this work would have been possible without my supervisors Dr. George Athwal and Dr. Jim Johnson, as well as my co-investigator Josh Giles. I would like to thank all of you for your efforts in completing this research.

Dr. Athwal and Johnson – I appreciate your help not only organizing and overseeing this research, but in helping prepare me for a career in orthopedic research. From advisory committee meetings, to rehearsal presentations, and constructive criticisms on manuscript preparation, the advice and assistance you have both provided will go a long way towards helping me start my own academic research practice.

Josh – thank you for your tremendous contributions to this work. The simulator that you have designed and continually improved on, your mastery of any and all software programs for data collection and analysis and your patience during our marathon testing sessions were all very much appreciated. I have no doubt that your future is bright and wish you well in all future endeavours.

To Dr. King, Dr. Canham and Dr. Johnson – thank you for your attentiveness and feedback during our communication course sessions. These sessions have certainly improved my understanding of some fundamental principles in biomechanical research, but have undoubtedly improved my personal communication and presentation skills. All presentations I have given since these sessions have been met with praise and I attribute this largely to your advice, so thank you.

I would also like to thank the Department of Medical Biophysics for being understanding of the challenges faced with being a graduate student and medical resident, particularly for being accommodating with course selections and alternate low-level comprehensive examinations.

Lastly, I would like to thank my wife, Lindsay. Thank you for being so helpful and patient with me while I took on yet another task that added stress to our lives and ate away at weekends and vacations over the past two years. This master's degree will be an integral part of my career, and our life, moving forward and I wouldn't have been able to complete it without your love and support.

Table of Contents

Abstract.....	ii
Co-Authorship Statement.....	iii
Acknowledgments.....	v
Table of Contents.....	vi
List of Tables.....	x
List of Figures.....	xi
Chapter 1.....	1
1 Introduction.....	1
1.1 The Shoulder.....	1
1.1.1 Osteology.....	1
Labrum, Capsule and Ligaments.....	7
1.2 Shoulder Kinematics.....	14
1.2.1 Static Stabilizers.....	14
1.2.2 Dynamic Stabilizers.....	16
1.3 Shoulder Instability.....	20
1.3.1 Pathophysiology.....	20
1.4 Treatment Options.....	28
1.5 Study Rationale.....	39
1.6 Objectives.....	40
1.7 Hypotheses.....	40
1.8 Thesis Overview.....	41
1.9 References.....	42
Chapter 2.....	52

2	Bristow versus Latarjet Coracoid Transfer for Recurrent Shoulder Instability with Glenoid Deficiency	52
2.1	Introduction.....	52
2.2	Materials & Methods	55
2.2.1	Specimen Preparation and Shoulder Simulator	55
2.2.2	Experimental Testing Protocol	58
2.2.3	Stability and Range of Motion.....	60
2.2.4	Outcome Variables & Statistical Analyses	61
2.3	Results.....	62
2.3.1	Joint Stiffness and Stability	62
2.3.2	Range of Motion	67
2.4	Discussion	69
2.5	Conclusion	72
2.6	References.....	73
	Chapter 3.....	76
3	Remplissage versus Latarjet Coracoid Transfer for Hill-Sachs defects: A Biomechanical Comparison	76
3.1	Introduction.....	76
3.2	Materials & Methods	77
3.2.1	Specimen Preparation	77
3.2.2	Shoulder Simulator	78
3.2.3	Surgical Protocol.....	79
3.2.4	Experimental Protocol & Outcome Variables	80
3.2.5	Data and Statistical Analysis	81
3.3	Results.....	81
3.3.1	Joint Stiffness.....	81
3.3.2	Range of Motion	85

3.3.3	Incidence of Dislocation	88
3.4	Discussion	90
3.5	Conclusions	93
3.6	References	94
Chapter 4	97
4	A Biomechanical Assessment of Superior Shoulder Translation after Reconstruction for Anterior Glenoid Bone Loss: The Latarjet Procedure versus Allograft Reconstruction.....	97
4.1	Introduction.....	97
4.2	Materials and Methods.....	100
4.2.1	Specimen Preparation	100
4.2.2	Shoulder Simulator	102
4.2.3	Testing Protocol	103
4.2.4	Stability Testing	106
4.2.5	Statistical Analysis.....	106
4.3	Results.....	107
4.3.1	Humeral Head Translation: Neutral Rotation.....	107
4.3.2	Humeral Head Translation: Internal Rotation.....	109
4.3.3	Humeral Head Translation: External Rotation	111
4.3.4	Humeral Head Translation: Load Effect.....	113
4.4	Discussion	113
4.5	Conclusion	117
4.6	References.....	118
Chapter 5	122
5	General Discussion & Conclusions.....	122
5.1	Bristow versus Latarjet Coracoid Transfer (Chapter 2).....	123
5.2	Remplissage versus Latarjet Coracoid Transfer (Chapter 3).....	124

5.3 Superior Shoulder Instability following Latarjet Coracoid Transfer (Chapter 4)	125
5.4 Cadaveric Testing	126
5.5 Conclusion	127
5.6 References.....	127
Appendix A: Glossary.....	130
Appendix B: Abbreviations List	132
Appendix C: Copyright Permissions	133
Curriculum Vitae	136

List of Tables

Table 2-1. Incidents of Glenohumeral Joint Dislocation during Two Stability Tests.	66
Table 3-1. Incidence of Dislocation following Anteroinferiorly Directed 80N Force.	89

List of Figures

Figure 1-1. Osteology of the Shoulder.....	2
Figure 1-2. Glenoid Retroversion and Inclination	4
Figure 1-3. Humeral Head Retroversion.....	6
Figure 1-4. Glenoid with Soft-tissue Restraints.....	9
Figure 1-5 Anterior view of Shoulder with Rotator Cuff Muscles.....	11
Figure 1-6 – Posterior view of Shoulder with Rotator Cuff Muscles	11
Figure 1-7. Glenohumeral Joint Concavity-Compression Effect.	18
Figure 1-8. Bankart Lesion and Hill-Sachs Defect.....	23
Figure 1-9. Hill-Sachs Defect Engagement in External Rotation.....	25
Figure 1-10. Bony Bankart Lesion.....	27
Figure 1-11. Bankart Stabilization.....	30
Figure 1-12. Bristow Coracoid Transfer.....	33
Figure 1-13. Latarjet Coracoid Transfer	35
Figure 1-14. Remplissage Procedure	37
Figure 2-1 – The Bristow and Latarjet Coracoid Transfers	54
Figure 2-2– In-vitro Shoulder Simulator.....	57
Figure 2-3. Anterior Glenohumeral Joint Stiffness in Adduction and Neutral or External Rotation.....	63

Figure 2-4. Anterior Glenohumeral Joint Stiffness in Abduction and Neutral or External Rotation.....	64
Figure 2-5. Axial Rotation in Adduction and Abduction, and Horizontal Extension in Abduction.....	68
Figure 3-1. Joint Stiffness in Adduction and Neutral Rotation	83
Figure 3-2. Joint Stiffness in Adduction and External Rotation.....	83
Figure 3-3. Joint Stiffness in Abduction and Neutral Rotation	84
Figure 3-4. Joint Stiffness in Abduction and External Rotation.....	84
Figure 3-5. Internal/External Range of Motion in Adduction	86
Figure 3-6. Internal/External Range of Motion in Abduction	86
Figure 3-7. Horizontal Extension Range of Motion in Abduction and External Rotation (60°)	87
Figure 4-1. Mounted Shoulder Specimen	101
Figure 4-2. Coracoid Reconstructions of a 30% Glenoid Defect	105
Figure 4-3. Superior Translation in Adduction and Neutral Rotation.	108
Figure 4-4. Superior Translation in Adduction and Internal Rotation.....	110
Figure 4-5. Superior Translation in Adduction and External Rotation.....	112

Chapter 1

1 Introduction

Overview: The purpose of this thesis will be to introduce the concept of anterior shoulder instability focusing on complex shoulder instability, which involves osseous defects of the shoulder that predispose to further instability. In this chapter, a brief overview of anatomy of the shoulder will be provided. Shoulder kinematics will also be reviewed, paying particular attention to the structures that serve as primary restraints to shoulder instability. Treatment options for primary and complex shoulder instability will briefly be reviewed. The objective, hypothesis, rationale and outline of the thesis will also be reviewed.

1.1 The Shoulder

The shoulder, primarily thought of as the glenohumeral joint, is a ball-and-socket joint that allows a wide range of multiaxial joint movement in all three planes (sagittal, coronal, axial or transverse) through a complex interaction of bones, supporting ligaments and surrounding musculature (1). It is the most mobile joint in the body and, as a result of being less constrained, is also the most frequently dislocated joint. There are a number of factors that contribute to its stability, which will be introduced here.

1.1.1 Osteology

The primary articulation of the shoulder, as stated above, is between the humeral head and the glenoid concavity of the scapula, representing the glenohumeral joint (Figure 1-1). However, the shoulder complex also includes the clavicle, or collar bone. Together, these three osseous structures define the shoulder, which has four major articulations: Sternoclavicular (SC) joint – between the sternum and clavicle; Acromioclavicular (AC) joint – between the scapula and clavicle; Glenohumeral joint – between the humeral head and glenoid; and the Scapulothoracic articulation – between the scapula and posterior rib cage. (2)

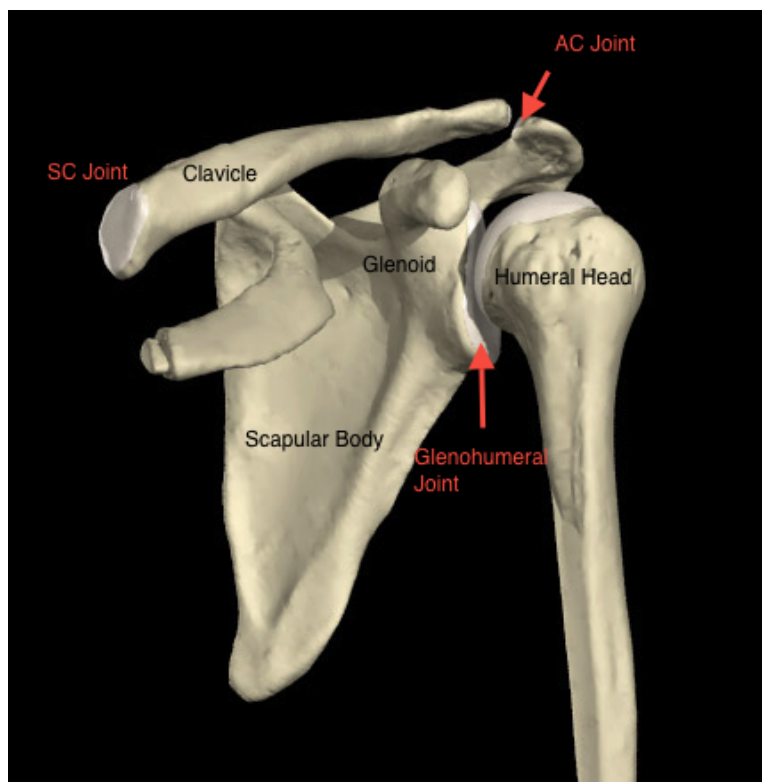


Figure 1-1. Osteology of the Shoulder

The shoulder joint is comprised of articulations between the clavicle, glenoid (scapula) and humeral head. Here we can see the acromioclavicular joint (AC joint), the glenohumeral joint, and the sternoclavicular joint (SC joint). Not pictured is the fourth articulation between the rib cage and the scapula, representing the scapulothoracic articulation. (3)

1.1.1.1 The Clavicle

The clavicle, an “S-shaped” bone, articulates medially with the sternum to make up the SC joint, and laterally with the acromion, an extension of the scapular spine, to form the AC joint. The clavicle serves as a site of muscular attachment and also acts as a strut to support the glenohumeral joint. The SC joint is the only true point of attachment of the shoulder girdle (or appendicular skeleton) to the trunk (or axial skeleton). Inferior migration of the shoulder complex is prevented through strong ligamentous attachments between the clavicle and coracoid (an extension of the scapula) (4).

1.1.1.2 The Scapula

The scapula is a broad, triangular bone that comprises the posterior aspect of the shoulder, overlying the 2nd through 7th posterior ribs (4). It serves as an attachment site for several muscles. Its anterior concave surface articulates with the posterior convexity of the ribs via muscular attachments, making up the scapulothoracic articulation, which stabilizes the scapula and provides support to the glenohumeral articulation.

Laterally, the scapula forms a flat projection, known as the glenoid fossa, which articulates with the humeral head, forming the glenohumeral joint. The glenoid fossa is relatively small, only 1/4 to 1/3 the size of the humeral head, and thus provides only a small contribution to glenohumeral joint stability on its own, relying heavily on the complex interaction of the static and dynamic stabilizers, which will be reviewed later in this chapter (5). The lack of constraint provided by the glenoid allows for such mobility of the glenohumeral joint. Relative to the axis of the scapula, the glenoid is retroverted approximately 4-12° (average of 7°) and is superiorly inclined approximately 5° (Figure 1-2). The scapula itself is 30-40° anteverted compared with the axis of the body (4).

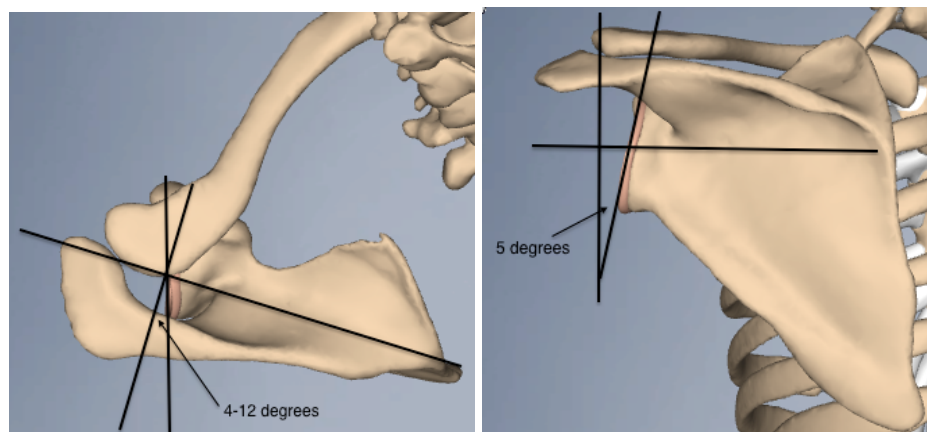


Figure 1-2. Glenoid Retroversion and Inclination

The glenoid has a variable orientation relative to the scapula in both axial/transverse and coronal planes. Looking on an axial view (left), the glenoid face is retroverted (averaging 4-12°) compared with the axis of the scapula. On a coronal view, the glenoid has a superior inclination averaging 5° compared with a vertical reference line. (3)

The superior process of the scapula, known as the scapular spine, separates two of the rotator cuff muscles, and also acts as a site of muscular attachment. This process continues laterally and anteriorly and becomes the acromion, which articulates with the clavicle (AC joint).

Anterior and medial to the glenoid, the scapula has an additional bony extension, known as the coracoid process which projects anteriorly and laterally. Often referred to as the “lighthouse” of the shoulder, this is an important anatomic reference point during surgery and serves as an attachment site for several ligaments and muscles that confer stability to the shoulder complex. Particularly important are the coracoclavicular ligaments, strong ligaments running between the coracoid and the clavicle that prevent inferior displacement of the shoulder girdle (coracoclavicular ligaments), and the coracohumeral ligament, running from the coracoid to the greater tuberosity which also prevents inferior humeral head displacement (4).

1.1.1.3 The Humerus

The humerus is the largest bone in the upper extremity. The proximal end, or humeral head, articulates with the glenoid. The head is retroverted relative to the humeral shaft (compared to trans-epicondylar axis of the distal humerus) by approximately 30° (Figure 1-3). The head has three distinct areas – the greater tuberosity (GT), lesser tuberosity (LT) and the bicipital groove located between them. The tuberosities represent insertion sites for the rotator cuff muscles, which dynamically stabilize the glenohumeral joint. As its name implies, the bicipital groove is the location where the long head of the biceps tendon runs, as it continues proximally to its insertion above the glenoid fossa. Slightly more distal along the humeral shaft, there is a region where the deltoid muscle inserts (deltoid tuberosity) (2).

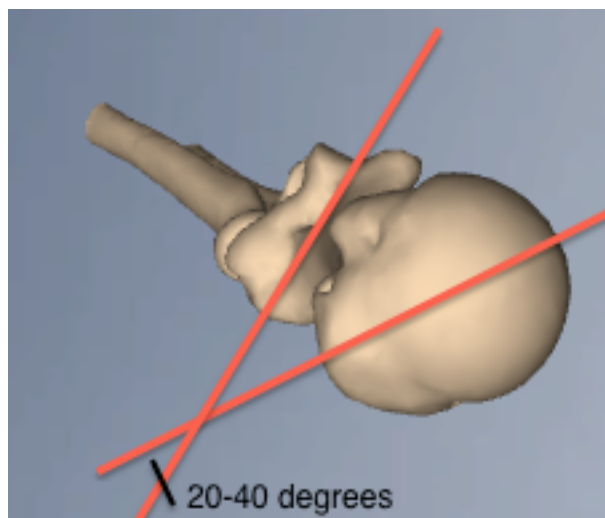


Figure 1-3. Humeral Head Retroversion

Axial, or overhead, view of the humerus demonstrating humeral head retroversion relative to the trans-epicondylar axis (line connecting the medial and lateral epicondyles of the distal humerus) (3)

Labrum, Capsule and Ligaments

1.1.1.4 Labrum

The glenoid labrum is a fibrocartilaginous complex attached circumferentially to the edge of the glenoid cavity (Figure 1-4). It serves to deepen the concavity of the glenoid by approximately 50% and contributes to shoulder stability by resisting translatory forces acting on the humeral head. Additionally, it serves as an attachment site for the glenohumeral ligaments and long head of the biceps (1,2). Disruptions of this structure are common following dislocation and are frequently associated with recurrent shoulder instability.

1.1.1.5 Joint Capsule

The articular capsule is a fairly loose, redundant structure that attaches around the scapular neck and inferior aspect of the neck of the humerus, near the lesser tuberosity. There are three focal areas of thickening of the capsule, known as the glenohumeral ligaments (GHL), that act as “check-reins” to excessive rotation or translation of the humerus. Running from the inferior aspect of the humeral head, or the humeral neck, these structures insert or coalesce with the glenoid labrum (4,6,7).

1.1.1.6 Superior Glenohumeral Ligament

The superior GHL, running from the supraglenoid tubercle above the glenoid face to the lesser tuberosity of the humerus, has a parallel course to the coracohumeral ligament (Figure 1-4). The two are felt to act together as a restraint to inferior translation and external rotation of the humeral head with the arm resting at one’s side (position of adduction) (4).

1.1.1.7 Middle Glenohumeral Ligament

The middle glenohumeral ligament is the most variable, with some patients having a so-called “cord-like” middle GHL, known as a “Buford complex”, and up to 30% of patients being deficient of this ligament altogether (4,8). It also runs from the supraglenoid tubercle to the lesser tuberosity, although some fibers coalesce with the subscapularis before its insertion on the lesser tuberosity (Figure 1-4) (9). Anatomical

studies have shown that as the arm moves away from the body, a motion known as abduction, the middle GHL becomes taut, limiting further external rotation of the humerus in this position. Maximal tension in the middle GHL is reached at approximately 45° of abduction, at which point it is also able to resist anterior translation of the humeral head in this position (10).

1.1.1.8 Inferior Glenohumeral Ligament

The inferior GHL is a hammock-like structure, with origins from both the anteroinferior and posteroinferior aspects of the glenoid (9). This ligament has two separate bands, an anterior and posterior band with an intervening segment of capsule. The anterior band inserts at the inferior margin of the articular surface of the humeral head, just below the lesser tuberosity. In abduction with the arm externally rotated, the so-called 'position of apprehension', the anterior band of the inferior GHL moves to the front of the shoulder where it is maximally taut and serves to resist anterior translation of the humeral head (9,11).

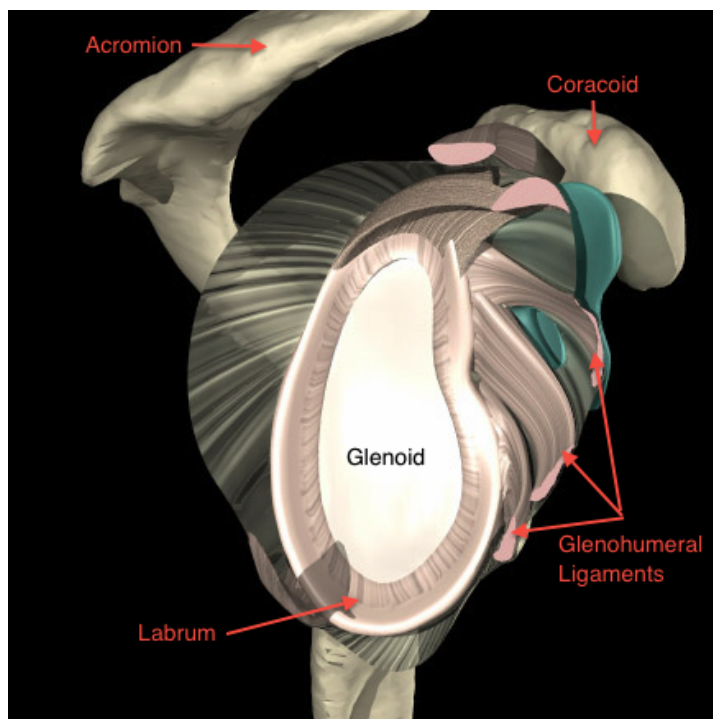


Figure 1-4. Glenoid with Soft-tissue Restraints

Sagittal view of the glenoid without overlying musculature, demonstrating the peripheral attachment of the glenoid labrum to the glenoid face. Also, the three glenohumeral ligaments (superior, middle and inferior) can be seen anterior to the glenoid, inserting with the labrum along the peripheral margin of the glenoid face (3)

1.1.1.9 Coracohumeral Ligament

The coracohumeral ligament (CHL) is a broad ligament originating from the superior portion of the joint capsule at the base of the coracoid process and inserting on the greater tuberosity. This acts in conjunction with the superior GHL, as described above, along with the anterior joint capsule to make up the “rotator interval”, which functions to resist inferior translation of the humeral head in adduction (1,12). The rotator interval structures also resist anterior translation with the arm in adduction.

1.1.1.10 Coracoacromial Ligament

The coracoacromial ligament (CAL) runs from the coracoid process to the anterior margin of the acromion. This structure provides a restraint against superior translation of the humeral head, largely in response to a superiorly directed force exerted axially on the humerus (13). Additionally, this structure, occasionally referred to as the more expansile coracoacromial “veil”, interacts with other structures of the rotator interval and prevents inferior translation of the humeral head (14).

1.1.1.11 Coracoclavicular Ligaments

Comprised of two separate bands, the trapezoid (lateral) and the conoid (medial) ligaments make up the complex commonly referred to as the coracoclavicular ligaments. As previously mentioned, these run from the superior edge of the coracoid process to the undersurface of the clavicle, and serve primarily as a restraint to inferior translation of the scapula, and subsequently the glenoid (4).

1.1.1.12 Muscles

The muscles surrounding the shoulder provide a component of dynamic stability, helping stabilize the joint while permitting motion. The rotator cuff is a muscular complex that surrounds the joint capsule and is comprised of the supraspinatus (superiorly), subscapularis (anteriorly), infraspinatus and teres minor muscles (posteriorly), which serves to provide a compressive load to stabilize the joint and facilitate motion (Figure 1-5 & 1-6).

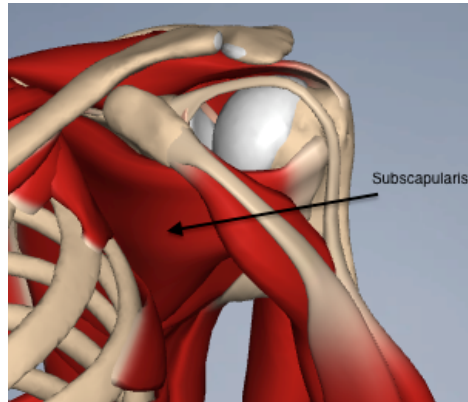


Figure 1-5 Anterior view of Shoulder with Rotator Cuff Muscles

Anterior view of the shoulder with surrounding rotator cuff musculature. Here, the subscapularis, responsible for internal rotation of the shoulder, can be seen anterior to the glenohumeral joint inserting on the lesser tuberosity of the humeral shaft (3)

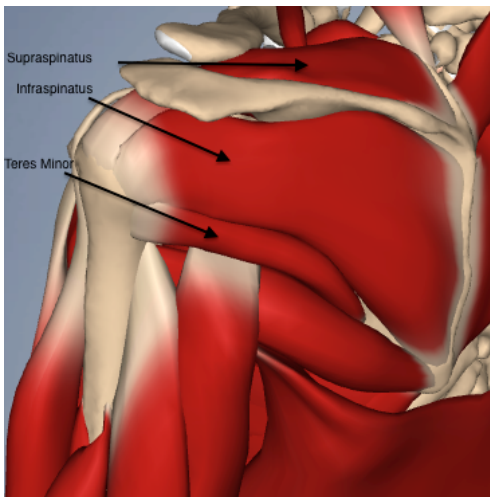


Figure 1-6 – Posterior view of Shoulder with Rotator Cuff Muscles

Posterior view of the shoulder with surrounding rotator cuff musculature. The supraspinatus, responsible for shoulder abduction, infraspinatus and teres minor, both responsible for shoulder external rotation, can be seen attaching to the greater tuberosity of the humeral shaft (3)

The supraspinatus originates in the supraspinatus fossa on the cranial side of the scapula, above the scapular spine and inserts on the greater tuberosity. It is innervated by the suprascapular nerve and is responsible for shoulder abduction.

The subscapularis muscle originates in the subscapularis fossa on the anterior aspect of the scapula and inserts on the lesser tuberosity. It is innervated by the upper and lower subscapular nerves and is responsible for internal rotation of the shoulder.

The infraspinatus and teres minor muscles originate on the posterior surface of the scapula and insert on the posterior aspect of the greater tuberosity. The infraspinatus is innervated by the suprascapular nerve, while the teres minor is innervated by the axillary nerve; together, these muscles are responsible for external rotation of the shoulder.

The long head of the biceps originates from the glenoid labrum at the supraglenoid tubercle, just above the glenoid articular surface, and runs in the bicipital groove between the greater and lesser tuberosities. It joins the short head of the biceps, which originates from the coracoid process, and runs down the humerus with a common muscle belly, inserting on the bicipital tuberosity of the radius. Together, the short and long heads are innervated by the musculocutaneous nerve and are responsible for elbow flexion and forearm supination.

In addition to the short head of the biceps, the coracobrachialis muscle also originates from the coracoid process. Together, the two are referred to as the conjoined tendon. The coracobrachialis muscle inserts distally on the humerus. It is also innervated by the musculocutaneous nerve and is responsible for forward elevation and adduction of the shoulder.

Overlying all of these muscles is the deltoid, separated from the rotator cuff by the subdeltoid bursa (fluid-filled sac). It has three separate heads: the anterior, arising from the lateral clavicle; the middle, arising from the acromion; and the posterior, arising from the scapular spine. The three heads have a common insertion, onto the deltoid tuberosity of the proximal humerus. The deltoid is innervated by the axillary nerve and is

responsible for forward flexion (anterior head), abduction (lateral head) and extension (posterior head) of the shoulder.

1.2 Shoulder Kinematics

As stated earlier, the shoulder is one of the most mobile joints in the body.

Motion of the shoulder includes:

1. Forward flexion ($\sim 160^\circ$) and extension ($\sim 60^\circ$) in the sagittal plane,
2. Abduction ($\sim 160^\circ$) and adduction in the coronal plane, and
3. Internal ($\sim 50^\circ$) and external rotation ($\sim 50^\circ$) in the horizontal or axial plane.

Abduction of the shoulder is a combined motion of both glenohumeral and scapulothoracic motion, occurring in a 2:1 ratio. For example, every 3 degrees of abduction is actually only 2 degrees of glenohumeral abduction and 1 degree of scapulothoracic abduction (15). This extensive range of motion is permitted through a complex interaction of static and dynamic stabilizers that work to minimize instability while facilitating motion (5,6,16).

1.2.1 Static Stabilizers

Static structures that contribute to shoulder stability include:

- a) Negative intra-articular pressure,
- b) Glenohumeral joint geometry,
- c) Labrum,
- d) Capsule and ligaments

Negative intra-articular pressure of the glenohumeral joint assists in stabilizing the humeral head within the glenoid fossa. This pressure occurs when the capsule remains an intact, closed compartment, and is attributable to the variable compliance of the structures that make up the joint. The glenoid itself is very firm, with only a thin layer of articular cartilage; however the labrum is very compliant and provides a 'suction-cup' effect (6). The magnitude of this effect is demonstrated in the lab setting where

creating a hole in the capsule, or “venting” the capsule, results in loss of this negative pressure and subsequent inferior translation of the humeral head up to 10mm at rest, and up to 50% increases in passive translation in all directions (17,18). While listed in the section of static stabilizers as it is a constantly negative pressure, there is a dynamic component to the intra-articular pressure. Some studies have shown that the pressure varies slightly with joint position, with the average pressure being -67.8 mm Hg, but decreasing to a maximum of -82.9 mm Hg in 20° of abduction (18).

Glenohumeral geometry also contributes to joint stability. Relative glenoid retroversion and superior inclination, as depicted earlier, provide bony restraints to anterior and inferior translation. Cadaveric studies have shown that 5-10° of superior inclination can significantly improve resistance to inferior translation. Similarly, glenoid retroversion provides resistance to anterior translation, with this effect maintained with a version of up to 5° of glenoid anteversion (19).

The glenoid labrum increases the depth of the glenoid concavity by ~50%, essentially providing a larger degree of conformity and constraint to the joint. Its consistency is variable, as it has been found to be more pliable and less rigidly attached around the anterosuperior aspect of the glenoid, while it is much more immobile and firmly attached at the inferior aspect of the glenoid providing a larger resistive force to translation (17). Additionally, the labrum serves to enhance the concavity-compressive effect, which will be explained below as it falls into the category of dynamic stability.

While the glenohumeral capsule has a surface area nearly double that of the humeral head and is fairly redundant, the focal thickenings, known as the glenohumeral ligaments, provide restraint to translation and rotation in different shoulder positions (5,7). The superior and middle GHJ are able to resist inferior and anterior translation in adducted or slightly abducted positions, while the anterior band of the inferior GHJ has the most significant effect in resisting anterior shoulder translation largely in an abducted position. Studies have shown that placing the shoulder in the position of apprehension, which is approximately 90° of abduction and external rotation, significantly increases the

stabilizing effect of this ligament with respect to anterior shoulder translation (2,5,7,17,20).

1.2.2 Dynamic Stabilizers

While the static structures exert their effect at the extremes of motion to prevent instability, the dynamic stabilizers act within the functional range of motion to provide stability where those static restraints are often lax (5,6). For example, the surrounding shoulder musculature attempts to optimally position the glenoid and provide a compressive force across the glenohumeral joint to keep the joint reduced providing stability while also permitting motion (5,7). The primary dynamic stabilizers include:

- a) Rotator cuff muscles,
- b) Long head of the biceps,
- c) Concavity-compression effect

Contraction of the rotator cuff muscles provides a compressive force across the joint, pulling the humeral head into the glenoid and also centering it within this concavity. The rotator cuff works via a ‘force-couple’, which predominantly has two actions – first is co-activation of agonist and antagonist muscles to centrally compress the joint and provide stability; the second involves controlled activation of agonistic muscles and relative inhibition of antagonists to allow controlled motion. During the second phase, the antagonist muscle remains active providing an eccentric stabilizing force to prevent displacement and instability (5,7,16,21).

Similarly, the long head of the biceps is also able to provide a compressive force across the joint. Its effect at reducing anterior and posterior translation in the adducted position has been demonstrated in cadaver-based investigations with loading of the long head while subsequently applying a translation force to the joint (22). Additionally, it was noted that in the setting of a capsulolabral injury, which typically occurs in association with a primary dislocation, that the stabilizing effect of the long head of the

biceps was greater than that provided by any of the rotator cuff muscles, particularly with the arm externally rotated (5,6,16,18,23).

Together, the rotator cuff and long head of the biceps contribute to stability by compressing the humeral head into the glenoid concavity. Lippitt and Matsen (1993) describe the concavity-compression effect well when comparing it to the compression and translation of a table tennis ball against a surface. A flat surface will not provide much resistance when attempting to translate the ball across the table. However, if the ball were compressed into a concavity on the table, the concavity increases the resistance to translation. This resistance increases as the depth of the concavity increases. Similarly, the labrum increases the depth of the glenoid concavity, therefore increasing the resistive force that it is able to provide in response to the glenoid compressive force and anterior translation (Figure 1-7). Therefore, injuries that lessen the depth of the concavity, such as a labral tear or glenoid rim fracture, decrease joint stability (21).

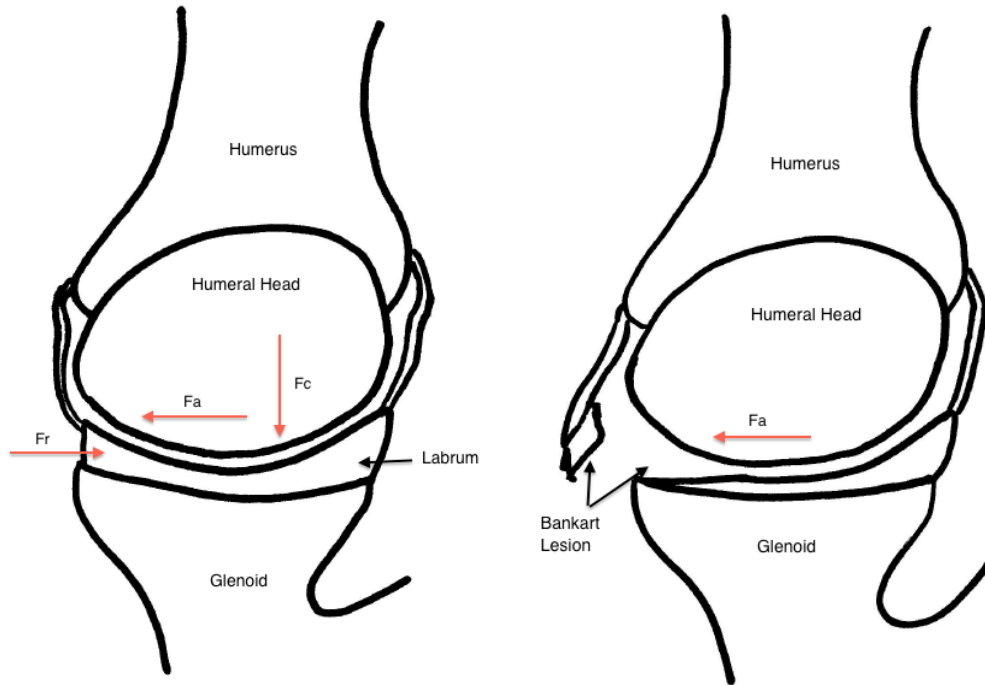


Figure 1-7. Glenohumeral Joint Concavity-Compression Effect.

Schematic diagram demonstrating the normal resistive force provided by the capsule and labrum (Fr) in response to an anterior translatory force applied to the humerus (Fa) (left). The concave shape of the glenoid and attached labrum help to contain the relatively spherical humeral head, providing resistance to translation. Additionally, the rotator cuff muscles and biceps provide a compression force (Fc) that keeps the humeral head centered in the glenoid concavity.

A labral tear (Bankart lesion), resulting in decreased concavity of the glenoid face and labrum, reduces the ability to resist translation (right) off-setting the balance resulting in anterior translation of the humeral head. (RMD)

Limitations of the concavity-compression effect are seen in the circumstances of weakness of the rotator cuff and injuries that further reduce the size of the glenoid relative to the humeral head (24). Decreases in rotator cuff muscle strength of 50% have been demonstrated to result in a 50% increase in anterior translation of the humeral head (25). The glenoid size contributes to the scapulohumeral balance, which is the concept that the glenoid must remain appropriately positioned to resist the forces applied through the humeral head to allow joint stability. A larger glenoid will have a larger effective glenoid arc or area that is able to support the net humeral joint reaction force (5,21,26).

1.3 Shoulder Instability

When the static and dynamic stabilizers fail and the balance between motion and stability is disrupted, often by an applied external force, the result is typically an anterior shoulder dislocation. While posterior and inferior dislocations can also occur, anterior dislocations make up 85-95% of all shoulder dislocations and will thus be the focus of this thesis (27,28).

The majority of dislocations occur in younger patients, with the average age of injury being in the 20's. Additionally, there is a male preponderance, representing 85-90% of all dislocations (27). The traditional mechanism of injury is often during sporting events in the aforementioned 'position of apprehension' with the arm abducted to approximately 90° and held in external rotation. A subsequent external rotation, and often extension, force is applied and levers the humeral head out of the glenoid concavity. However, additional patients may experience dislocations after a fall onto their outstretched hand or onto their adducted shoulder, although these mechanisms are not as common. Atraumatic dislocations can occur, particularly in those experiencing multi-directional instability with predisposing factors, such as ligamentous laxity. These dislocations represent the minority, and will not be discussed.

1.3.1 Pathophysiology

Typically, a shoulder dislocation will result from failure of one of the stabilizing structures. Although initially soft-tissue injuries were thought to be the primary pathology involved, it is now being recognized that bony restraints are equally involved and injured.

1.3.1.1 Soft-Tissue Pathology

Elderly patients frequently experience a disruption of the rotator cuff with their initial dislocation (27). In younger patients, the majority of dislocations are associated with tearing of the capsule and/or labrum – commonly called a ‘capsulolabral’ injury – away from the anterior glenoid rim. This lesion, first described in 1923 by Bankart and referred to by subsequent authors as a “Bankart lesion”, has been identified in 84-90% of patients following their initial dislocation (27). The location of capsule and labrum involved is typically at the insertion of the anterior band of the inferior GHJ and middle GHJ at the anteroinferior portion of the glenoid rim, with injury to these structures often part of the primary dislocation (Figure 1-7 above) (29). With these structures involved, the shoulder's ability to resist anterior translation, particularly with the arm abducted, is dramatically reduced and the patient is predisposed to future dislocations. In fact, resection of the labrum alone was found to reduce the resistance to anterior translation by 20% (24). An additional cadaveric study examined the effect of a chondrolabral lesion on glenoid depth and shoulder stability, and found reductions of 80% and 65% respectively, significantly decreasing shoulder stability in this setting (30).

1.3.1.2 Bony Pathology – Complex Instability

In addition to the soft-tissue pathology, anterior dislocations are frequently associated with osseous lesions of the humeral head, glenoid, or both. When bony lesions contribute to ongoing shoulder instability, it is appropriately known as ‘complex instability’. In recent years, attention has been drawn to identification and management of these osseous lesions because of their reported contribution to failure of soft-tissue targeted stabilization procedures, with recurrence rates of up to 67% when these lesions are not addressed (30–36)

With disruption of the anterior capsulolabral structures, the humeral head is able to translate anteriorly and inferiorly as it dislocates from the glenoid fossa. The posterolateral aspect of the humeral head then impacts on the anterior glenoid rim (37). The humeral head is largely made up of less dense, cancellous bone and experiences impaction as it contacts the dense, cortical bone of the glenoid rim. This

impaction fracture of the posterolateral humeral head, now known commonly as a Hill-Sachs lesion, has been described throughout history (Figure 1-8). The earliest description appeared in 1861 by Flowers, but it was not until 1940 when Hill and Sachs published a concise review that the lesion adopted their names (26,37,38). This lesion has been identified in up to 90% of patients following initial dislocations and 100% of patients experiencing recurrent instability (37,39,40).

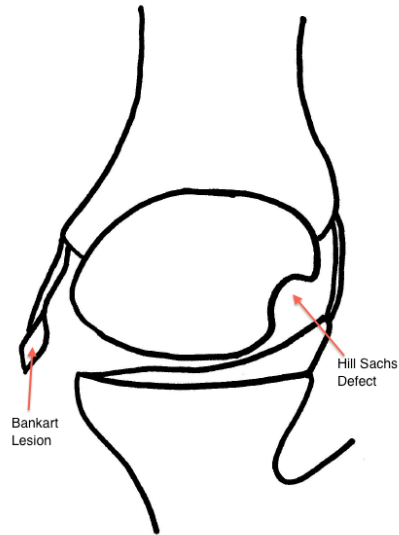


Figure 1-8. Bankart Lesion and Hill-Sachs Defect

An axial, or overhead, view of the glenohumeral joint following traumatic anterior glenohumeral dislocation. Both pathognomonic lesions that result (anterior Bankart lesion and posterior Hill-Sachs defect) are visualized. (RMD)

Although the effect of the Hill-Sachs lesion is variable and depends largely on its size, defects can 'engage' the anterior glenoid rim facilitating recurrent instability (32,37,41). The term 'engage', described by Burkhart and De Beer, simply means that in certain arm positions, mostly abduction and external rotation, the axis of the Hill-Sachs lesion will match that of the anterior glenoid rim, allowing the humeral head to translate anteriorly over the glenoid rim as the defect 'engages' the rim (Figure 1-9) (32,37). As a result, the Hill-Sachs lesion has been recognized as a significant contributor to failed surgical stabilization if it is not appropriately addressed (31,32,35,41,42).

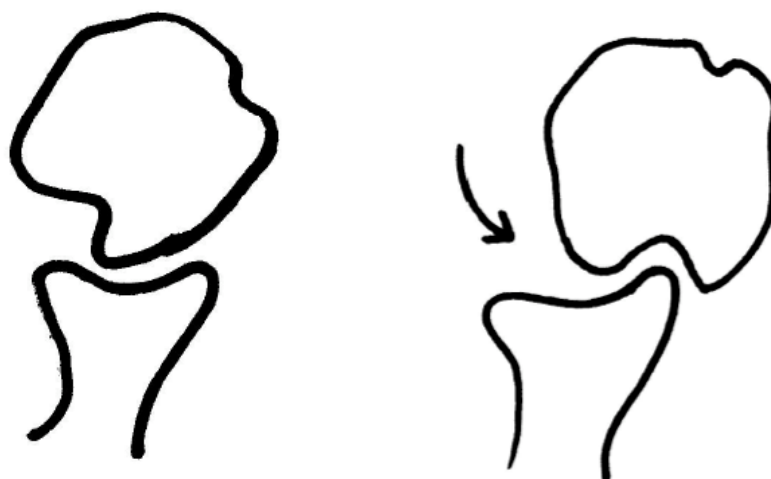

Figure 1-9. Hill-Sachs Defect Engagement in External Rotation

Axial (overhead) view of the glenohumeral joint following a traumatic anterior dislocation demonstrating the typical location for a posterior Hill-Sachs defect (left). As the shoulder externally rotates, the orientation of the Hill-Sachs defect aligns with the anterior margin of the glenoid. With slight anterior translation that occurs as the arm continues to externally rotate, the Hill-Sachs defect can translate over the glenoid edge, resulting in engagement of that defect (right) which could facilitate shoulder dislocation. (RMD)

Glenoid defects may result from either attritional wear with bone loss from repetitive dislocations, or an acute avulsion fracture of the anterior glenoid rim with the attached capsulolabral complex (36,43). Because this is often seen as an extension of the capsulolabral injury, it is frequently referred to as a 'bony Bankart' lesion (Figure 1-10) (42,44). Glenoid defects are seen in 22% of patients following their initial dislocation (39) and in up to 75% of those experiencing recurrent shoulder instability (35,36,45)(35,36). Similar to the Hill-Sachs lesion, the effect of anterior glenoid bone loss is variable, and often depends on the size of the segment involved. Loss of a segment of the glenoid reduces the effective glenoid arc length and the compressive-concavity restraint, reducing the glenoid's ability to resist axial forces transmitted by the humeral head (36,43). As a result, the ability to resist anterior translation is reduced, especially with co-existing injury to the capsulolabral structures, and the shoulder is prone to recurrent instability (44).

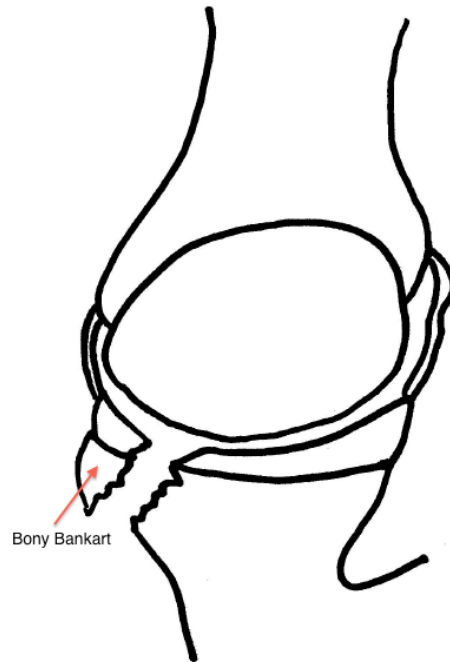


Figure 1-10. Bony Bankart Lesion

Following a traumatic anterior shoulder dislocation, occasionally a more significant anterior injury can occur involving a portion of the glenoid rim. On this axial (overhead) diagram, a bony Bankart lesion can be seen along the anterior glenoid rim where a segment of the glenoid rim has been sheared off with the attached labrum. This reduces the ability of the glenoid to resist anterior translation of the humeral head, predisposing to further episodes of shoulder instability. (RMD)

1.4 Treatment Options

1.4.1.1 Immobilization

Initial management of an acute shoulder dislocation involves immediate reduction. Following this, some have advocated for a period of immobilization of 3 or more weeks in a sling, while others have only utilized a sling in the acute phase (1 week) for patient comfort (46–50). Debate also existed over whether splinting in a position of abduction and external rotation would improve Bankart healing against the glenoid neck. Immobilization was also typically followed by physiotherapy focusing on range of motion and strengthening of the shoulder and eventual return to sport/activities. While a consensus was lacking early on for the appropriate duration of immobilization, meta-analyses have shown a lack of benefit of sling immobilization beyond 1 week post-injury and that the benefit of holding the limb in abduction and/or external rotation was not reproducible among different populations (50).

1.4.1.2 Bankart Repair (Soft-tissue Stabilization)

Following initial immobilization, further debate existed as to when patients should receive surgical referrals. Two theories existed, the first being an urgent referral to consider stabilization following the initial dislocation, or alternatively, a “wait-and-see” approach could be taken to see if recurrent instability developed, warranting referral and eventual surgical stabilization (51). Stabilization procedures could then be performed either open or arthroscopically, with the aim being to repair the Bankart lesion by reattaching the torn labrum and capsule to the anterior glenoid rim, typically utilizing suture anchors (Figure 1-11). Suture anchors, which are small threaded screws with attached suture material, are placed into the glenoid rim in the region where the labrum has been detached (Bankart lesion). The suture material is then passed around the labrum and glenohumeral ligaments and used to pull these tissues back down to the bony glenoid rim. This restores the “bumper effect” provided by the anterior labrum to resist translation of the humeral head, re-tensions the glenohumeral ligaments in the at-risk positions, and restores the compressive-concavity restraint of the joint (24,52,53).

Several studies investigated acute versus delayed stabilization and found that the procedures were equally effective in both groups, but that perhaps a certain subset of patients (*i.e.* younger, with riskier sports like rugby or football) would benefit from stabilization after their initial dislocation (51,53,54). Overall success rates for a Bankart repair have been reported as 85 – 90% (55–57), with a recent long-term study indicating no significant differences between recurrence rates for the arthroscopic and open procedures, 11% and 8% respectively, after a mean follow-up of 11 years (58).

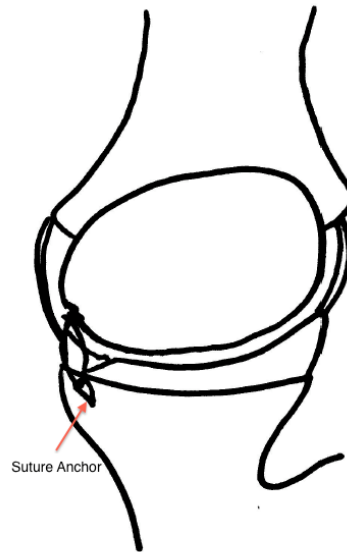


Figure 1-11. Bankart Stabilization

Treatment of anterior shoulder instability utilizing a soft-tissue Bankart repair (stabilization) with suture anchors. Pictured here, small suture anchors (screws with attached suture material) are placed into the anterior margin of the glenoid, with the sutures then passed around the labrum and capsule that were sheared off as part of the Bankart lesion. The sutures are then used to tie the labrum and capsule down to bone to restore their stabilizing effect. (RMD)

While the debate over which Bankart repair technique is best, open or arthroscopic, has still not been convincingly settled, Burkhart and De Beer astutely noted that failure rates of primary stabilization were substantially higher with both techniques when associated osseous injuries of the glenoid or humeral head were not identified and managed in conjunction with the Bankart lesion (32). When they retrospectively analyzed their long-term outcomes following Bankart repair, they found 67% of patients with osseous defects of either the glenoid or humeral head experienced a recurrent episode of instability, compared to only 4% of those who did not have these associated lesions (32). More recently, Balg and Boileau (2007) have confirmed the significance of associated lesions of the humeral head or glenoid after retrospective review of a cohort of patients following soft-tissue repair, noting increased rates of recurrent instability in those with Hill-Sachs lesions or glenoid defects as well. They have included both injuries as salient points on the 'Instability Severity Index Score', a tool they designed to help identify patients that would benefit from open surgical stabilization to address bony deficits (59).

The results of these studies have shifted attention towards managing these associated osseous lesions that predispose to further episodes instability. However, critical defect values and the corresponding standard of care for each are still being defined, with numerous treatment options currently available.

1.4.1.3 Glenoid Arc Reconstruction

Around the time that Burkhart and De Beer noted the increased rate of recurrent shoulder instability associated with osseous injuries, Itoi et al. (2000) (33) performed a cadaveric study looking at the stability provided with a standard Bankart repair in the setting of increasing glenoid defects. They found that once a critical defect value of 21% of the width of the glenoid was surpassed, that an isolated Bankart repair was insufficient in restoring stability and that alternative procedures to address the glenoid defect would be required (33). Other studies have confirmed that defects >25% would benefit from glenoid arc reconstruction (60,61). A variety of procedures have been described in the

literature, with the most prevalently utilized being the Bristow and Latarjet coracoid transfers. Additional procedures have included iliac crest bone graft reconstruction or allograft bone reconstruction, although they are both not as common as the coracoid transfers and will not be described here.

The Bristow coracoid transfer was initially described in 1958 by Helfet, but named after his mentor Rowley Bristow (62). The initial description of the procedure involved osteotomizing the distal half-inch of the coracoid maintaining its attached conjoined tendon. A small vertical split was then made in the subscapularis tendon to pass the coracoid segment, with its attached tendon, through this split and against the anterior inferior glenoid rim (Figure 1-12). It was secured by incorporating the conjoined tendon in the subscapularis repair (62–64). The primary effect of this, once healed, was to allow the conjoined tendon to provide a sling-like buttress anteriorly, enhanced with the arm in an abducted position, essentially mimicking the function of the middle and inferior glenohumeral ligaments (64). Additionally, with the passage of the graft through a split in the subscapularis, the inferior fibers of the subscapularis are also tensioned as the arm is abducted to further resist anterior translation. The description of the Bristow was later modified by May to include single screw fixation along the axis of the coracoid fragment (“standing position”) with the undersurface of the coracoid sitting flush with the glenoid face (65,66). In addition to the sling-effect of the conjoint tendon, this modification added the benefit of an anterior bone block, which was more consistent with descriptions of the Latarjet procedure, explained below. Early results of the Bristow procedure, reported by Hovelius et al., reported a 90% success rate (67).

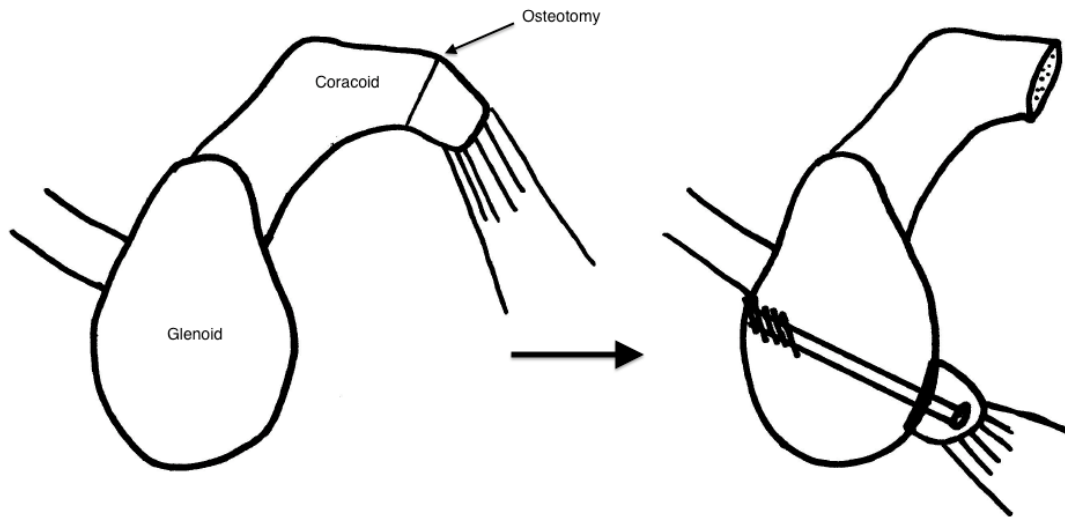


Figure 1-12. Bristow Coracoid Transfer

Here, a sagittal projection of the glenoid and coracoid process are shown (left) with their normal anatomic relationship. A projected osteotomy line is also noted on the coracoid process. Next, the final construct for a Bristow coracoid transfer (65) is depicted (right) with the coracoid process cut and transposed to the anterior-inferior aspect of the glenoid rim where it is held with a single cortical screw. (RMD)

Latarjet (1954) had described a similar procedure to Helfet's a few years prior, involving a coracoid transfer and passing this segment with its attached conjoined tendon through a split in the subscapularis as well (68). However, Latarjet's technique involved utilizing the entire horizontal component of the coracoid, and re-orienting the fragment, fixing it such that the inferior surface of the coracoid was held against the scapular neck with two screws (Figure 1-13) (63,64). Similarly, this allowed both a bony block effect to increase the articular arc that is able to resist compressive forces by the humerus, while also providing the sling-effect of the conjoined tendon and lower subscapularis in the abducted and externally rotated positions to resist anteroinferior translation or dislocation (69–71). This procedure carried a reported success rate of up to 95% (41,66).

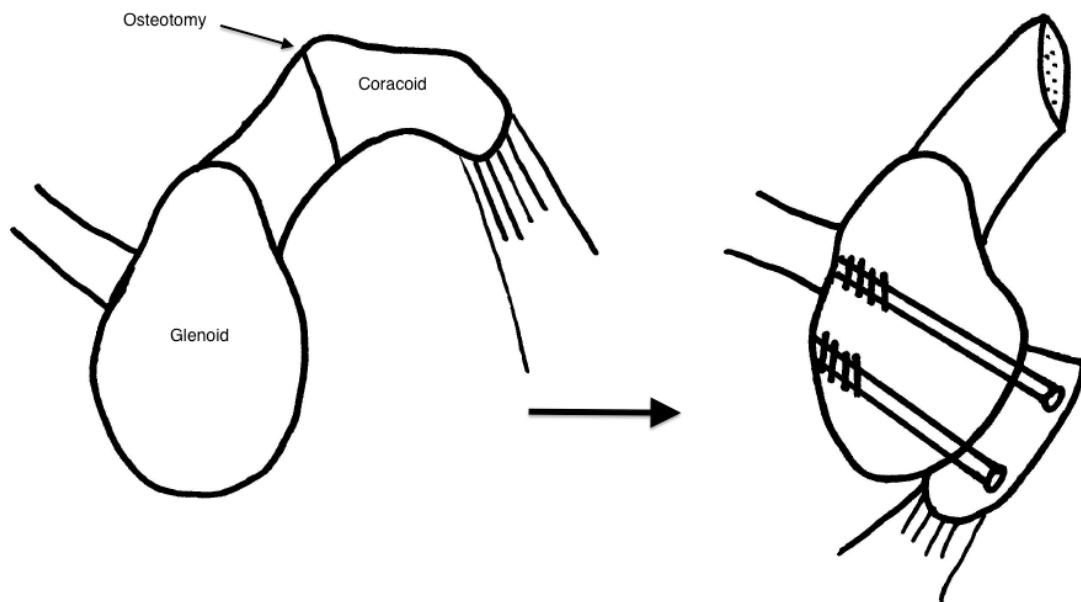


Figure 1-13. Latarjet Coracoid Transfer

A sagittal projection of the glenoid and coracoid process are shown (left) with their normal anatomic relationship. A projected osteotomy line is also noted on the coracoid process, found to be farther from its tip relative to the diagrammatic representation of the Bristow coracoid transfer. Next, the final construct for a Latarjet coracoid transfer is depicted (right) with the coracoid process cut and transposed to the anterior-inferior aspect of the glenoid rim where it is held with two cortical screws. (RMD)

1.4.1.4 Humeral Head Reconstruction

Similar to the glenoid defect, the significance of the humeral Hill-Sachs lesion increases with its size. It has been commonly accepted that small lesions (<20-25% of humeral head width) can generally be treated with benign neglect, simply managing the associated soft-tissue Bankart lesion with either arthroscopic or open stabilization with relatively good success (37,72,73). Alternatively lesions >40% are almost always seen as clinically significant and at risk of “engaging” the glenoid rim, facilitating a dislocation. Cadaveric studies have confirmed that defects of this size reproducibly lead to increased shoulder instability (34,74). As a result, lesions of this size are generally treated surgically with one of several options, including bone grafting (allograft) or rotational osteotomies of the proximal humerus (37). Lesions between 20-40% represent a current ‘gray-zone’, although additional factors, such as the orientation of the defect and the presence of additional capsulolabral injuries, may contribute to instability associated with these lesions and often require them to be managed surgically (37,74,75). Common treatment options for these slightly smaller defects include the remplissage procedure and the Latarjet coracoid transfer, both which attempt to limit Hill-Sachs defect engagement.

Remplissage is a French term, which means simply ‘filling’. This procedure, initially described by Connolly in 1972, involves imbricating the infraspinatus and posterior capsule into the Hill-Sachs defect with suture anchors (Figure 1-14) (76,77). This essentially makes the lesion extra-articular so that it can no longer engage the anterior glenoid rim as a result of the “bumper” of soft-tissue created. Additionally, the posterior soft tissues act as a tether to reduce the amount of anterior translation in the shoulder, again preventing dislocation (77). Purchase et al. (2008) described an arthroscopic version of this procedure, which was subsequently modified by Koo et al. (2009) to include a double anchor construct. (78,79).

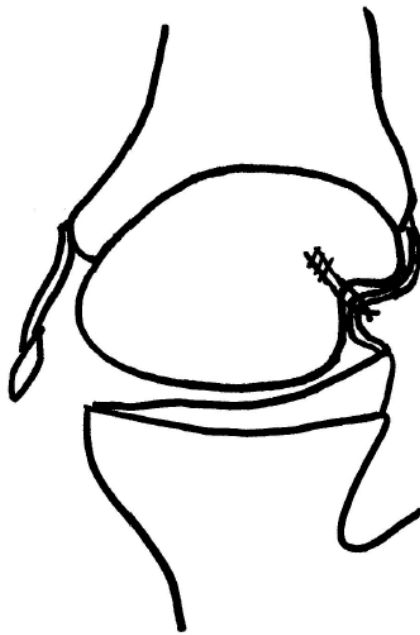


Figure 1-14. Remplissage Procedure

Schematic representation of a shoulder following anterior dislocation with associated Bankart and Hill-Sachs defect. The Hill-Sachs defect has been treated with the remplissage procedure with a suture anchor placed into the defect and the overlying posterior capsule and infraspinatus tendon sutured into the defect to limit external rotation and anterior translation to prevent it from engaging the anterior glenoid rim. (RMD)

Regardless of the individual technique modifications, the effect remains the same, which is to reduce the ability of the Hill-Sachs defect to engage the glenoid rim. Biomechanical cadaveric studies have shown that in conjunction with a Bankart repair, the addition of the remplissage procedure helped to significantly improve shoulder stability with a 30% Hill-Sachs defect (80). Clinical studies have also confirmed the success of the procedure with instability recurrence rates of only 2-8% in long-term follow-up (77,78).

The Latarjet coracoid transfer, as described in the previous section, can also be performed in the setting of an engaging Hill-Sachs defect. The goal of the procedure is to provide the same sling-effect instilled by the conjoined tendon and subscapularis, but also to increase the articular arc length to prevent the humeral head from engaging the glenoid (37,42). The biomechanical and clinical effects of this procedure for an engaging Hill-Sachs defect are not well defined.

1.5 Study Rationale

While numerous treatment options have been described in the management of complex shoulder instability, evidence to support their use has largely been limited to reports involving small numbers of patients, while only occasional long-term reports have been identified. Few comparative studies of these procedures exist, particularly focusing on the biomechanics of the repairs.

As demonstrated above, glenoid defects following an anterior shoulder dislocation with an associated capsulolabral injury have been clinically suspected, and cadaverically demonstrated, to be a cause for recurrent dislocation when managed with a simple Bankart repair (32,33). It has been accepted that glenoid defects >25% of the total width should be addressed, with the recommended treatment being a coracoid transfer, often referred to as a “Bristow-Latarjet” coracoid transfer (44,59,61,71,81–83). These procedures have frequently been referred to synonymously, and their success collectively has been well documented (66,67,84). However, their technical descriptions have differed, as outlined above, while their biomechanical equivalence has never been demonstrated.

Similarly, Hill-Sachs lesions of the humeral head have also been associated with recurrent dislocations following soft-tissue stabilization procedures (31,32,35,41,76). As identified, larger lesions, generally >20% of humeral head width, are best treated surgically, although the best procedure for this size of defect has not been determined. Presently, clinical focus has been on two of the described treatment options – the remplissage procedure, and the Latarjet coracoid transfer, as detailed above. Both reportedly have had reasonable success rates, although no comparative studies exist to determine which is clinically or biomechanically superior.

Finally, while the Latarjet coracoid transfer potentially represents a treatment option for both engaging Hill-Sachs lesions and large glenoid defects, the only procedural complications usually listed are related to technical points, such as acute neurological injury (usually to the musculocutaneous nerve) or graft fracture, or related to long-term

sequelae such as graft non-union (63,64). Limited descriptions of deleterious biomechanical effects of the procedure exist particularly on the effect that resection of the coracoacromial ligament may have on superior shoulder stability.

1.6 Objectives

The objectives of this thesis were threefold:

1. To compare the stabilizing effect of the Bristow coracoid transfer and the Latarjet coracoid transfer in the setting of an intact glenoid, and with 15% and 30% glenoid defects,
2. To compare the stabilizing effect of the remplissage and Latarjet coracoid transfer in the setting of an engaging 25% Hill-Sachs defect, and
3. To compare the degree of superior shoulder instability following Latarjet coracoid transfer and alternative bone block procedures not requiring coracoacromial ligament resection.

1.7 Hypotheses

The hypotheses for the above objectives were:

1. The Latarjet coracoid transfer will provide improved shoulder stability in comparison to the Bristow coracoid transfer for all glenoid defect states.
2. The Latarjet coracoid transfer will provide improved shoulder stability, and less restricted range of motion compared to the remplissage procedure in the treatment of an engaging Hill-Sachs defect.

3. The Latarjet coracoid transfer will result in greater superior shoulder migration compared to bone augmentation procedures that do not violate the coracoacromial ligament.

1.8 Thesis Overview

Chapter 2 compares the Bristow and Latarjet coracoid transfers for various glenoid defect states. Chapter 3 compares the remplissage and Latarjet procedures for treatment of an engaging Hill-Sachs lesion. Chapter 4 compares the degree of superior translation conferred by performing the Latarjet versus bone grafting procedures that preserve the coracoacromial ligament. Chapter 5 provides a general discussion, summary of findings and potential future areas of work.

1.9 References

1. Tortora GJ, Grabowski SR. Principles of Anatomy and Physiology, Tenth Edition. 10th ed. Roesch B, editor. Hoboken, NJ: John Wiley & Sons, Inc.; 2003. p. 1104.
2. Swarm DL, Mahar AT, Weichel DW, Pedowitz RA. Shoulder Anatomy and Biomechanics. In: Pedowitz RA, Johnson DH, editors. Practical Orthopaedic Sports Medicine & Arthroscopy. Pennsylvania, PA: Lippincott Williams & Wilkins; 2007. p. 145–56.
3. PrimalPicturesLtd. 3D Anatomy images. Riverwoods, Illinois: Primal Pictures Ltd.; 2006.
4. Terry GC, Chopp TM. Functional Anatomy of the Shoulder. Journal of Athletic Training. 2000;35(3):248–55.
5. Abboud JA, Soslowsky LJ. Interplay of the static and dynamic restraints in glenohumeral instability. Clinical orthopaedics and related research. 2002 Jul;(400):48–57.
6. Hurov J. Anatomy and mechanics of the shoulder: review of current concepts. Journal of hand therapy □: official journal of the American Society of Hand Therapists. 2009;22(4):328–42; quiz 343.
7. Plausinas D, Jazrawi LM, Zuckerman JD, Rokito AS. Anatomy and Biomechanics of the Shoulder. In: Schepsis AA, Busconi BD, editors. Sports Medicine. Pennsylvania, PA; 2006. p. 169.
8. Williams MM, Snyder SJ, Buford D. The Buford complex--the “cord-like” middle glenohumeral ligament and absent anterosuperior labrum complex: a normal anatomic capsulolabral variant. Arthroscopy □: the journal of arthroscopic & related surgery □: official publication of the Arthroscopy Association of North America and the International Arthroscopy Association. 1994 Jun;10(3):241–7.
9. Burkart AC, Debski RE. Anatomy and function of the glenohumeral ligaments in anterior shoulder instability. Clinical orthopaedics and related research. 2002 Jul;(400):32–9.

10. Felli L, Biglieni L, Fiore M, Coviello M, Borri R, Cutulo M. Functional study of glenohumeral ligaments. *Journal of orthopaedic science*: official journal of the Japanese Orthopaedic Association. 2012 Sep;17(5):634–7.
11. Pope EJ, Ward JP, Rokito AS. Anterior shoulder instability - a history of arthroscopic treatment. *Bulletin of the NYU hospital for joint diseases*. 2011 Jan;69(1):44–9.
12. Hunt SA, Kwon YW, Zuckerman JD. The rotator interval: anatomy, pathology, and strategies for treatment. *The Journal of the American Academy of Orthopaedic Surgeons*. 2007 Apr;15(4):218–27.
13. Hockman DE, Lucas GL, Roth CA. Role of the coracoacromial ligament as restraint after shoulder hemiarthroplasty. *Clinical orthopaedics and related research*. 2004 Feb;(419):80–2.
14. Moorman CT, Warren RF, Deng XH, Wickiewicz TL, Torzilli PA. Role of coracoacromial ligament and related structures in glenohumeral stability: a cadaveric study. *Journal of surgical orthopaedic advances*. 2012 Jan;21(4):210–7.
15. Hoppenfeld S. *Physical Examination of the Shoulder*. *Physical Examination of the Spine & Extremities*. Upper Saddle River, NJ: Prentice Hall, Pearson Education; 1976. p. 1–34.
16. Labriola JE, Lee TQ, Debski RE, McMahon PJ. Stability and instability of the glenohumeral joint: the role of shoulder muscles. *Journal of shoulder and elbow surgery / American Shoulder and Elbow Surgeons ... [et al.]*. 2005;14(1 Suppl S):32S–38S.
17. Curl LA, Warren RF. Glenohumeral joint stability. Selective cutting studies on the static capsular restraints. *Clinical orthopaedics and related research*. 1996 Sep;(330):54–65.
18. Alexander S, Southgate DFL, Bull AMJ, Wallace AL. The role of negative intraarticular pressure and the long head of biceps tendon on passive stability of the glenohumeral joint. *Journal of shoulder and elbow surgery / American Shoulder and Elbow Surgeons ... [et al.]*. 2013 Jan;22(1):94–101.
19. Kikuchi K, Itoi E, Yamamoto N, Seki N, Abe H, Minagawa H, et al. Scapular inclination and glenohumeral joint stability: a cadaveric study. *Journal of*

- orthopaedic science □: official journal of the Japanese Orthopaedic Association. 2008 Jan;13(1):72–7.
20. Blasier RB, Guldborg RE, Rothman ED. Anterior shoulder stability: Contributions of rotator cuff forces and the capsular ligaments in a cadaver model. *Journal of shoulder and elbow surgery / American Shoulder and Elbow Surgeons ... [et al.]*. 1992 May;1(3):140–50.
 21. Lippitt SB, Matsen FA. Mechanisms of glenohumeral joint stability. *Clinical orthopaedics and related research*. 1993 Jun;(291):20–8.
 22. Itoi E, Motzkin NE, Morrey BF, An KN. Stabilizing function of the long head of the biceps in the hanging arm position. *Journal of shoulder and elbow surgery / American Shoulder and Elbow Surgeons ... [et al.]*. 1994 May;3(3):135–42.
 23. Itoi E, Newman SR, Kuechle DK, Morrey BF, An KN. Dynamic anterior stabilisers of the shoulder with the arm in abduction. *The Journal of bone and joint surgery. British volume*. 1994 Sep;76(5):834–6.
 24. Lippitt SB, Vanderhooft JE, Harris SL, Sidles JA, Harryman DT, Matsen FA. Glenohumeral stability from concavity-compression: A quantitative analysis. *Journal of shoulder and elbow surgery / American Shoulder and Elbow Surgeons ... [et al.]*. 1993 Jan;2(1):27–35.
 25. Wuelker N, Korell M, Thren K. Dynamic glenohumeral joint stability. *Journal of shoulder and elbow surgery / American Shoulder and Elbow Surgeons ... [et al.]*. 1998;7(1):43–52.
 26. Matsen FA, Thomas SC, Rockwood Jr CA, Wirth MA. Glenohumeral Instability. In: Rockwood Jr CA, Matsen FA, Wirth MA, Harryman DT, editors. *The Shoulder*. 2nd ed. Philadelphia, PA: W.B. Saunders Company; 1998. p. 611–754.
 27. Liu SH, Henry MH. Anterior shoulder instability. Current review. *Clinical orthopaedics and related research*. 1996 Feb;(323):327–37.
 28. Mahaffey BL, Smith PA. Shoulder instability in young athletes. *American family physician*. 1999 May 15;59(10):2773–82, 2787.
 29. Bicos J, Mazzocca AD, Arciero RA. Anterior Instability of the Shoulder. In: Schepsis A, Busconi B, editors. *Sports Medicine*. 2006. p. 214.

30. Lazarus MD, Sidles JA, Harryman DT, Matsen FA. Effect of a chondral-labral defect on glenoid concavity and glenohumeral stability. A cadaveric model. *The Journal of bone and joint surgery. American volume.* 1996 Jan;78(1):94–102.
31. Boileau P, Villalba M, Héry JY, Balg F, Ahrens P, Neyton L. Risk factors for recurrence of shoulder instability after arthroscopic Bankart repair. *The Journal of bone and joint surgery. American volume.* 2006 Aug;88(8):1755–63.
32. Burkhart SS, De Beer JF. Traumatic glenohumeral bone defects and their relationship to failure of arthroscopic Bankart repairs: significance of the inverted-pear glenoid and the humeral engaging Hill-Sachs lesion. *Arthroscopy: the journal of arthroscopic & related surgery: official publication of the Arthroscopy Association of North America and the International Arthroscopy Association.* 2000 Oct;16(7):677–94.
33. Itoi E, Lee SB, Berglund LJ, Berge LL, An KN. The effect of a glenoid defect on anteroinferior stability of the shoulder after Bankart repair: a cadaveric study. *The Journal of bone and joint surgery. American volume.* 2000 Jan;82(1):35–46.
34. Kaar SG, Fening SD, Jones MH, Colbrunn RW, Miniaci A. Effect of humeral head defect size on glenohumeral stability: a cadaveric study of simulated Hill-Sachs defects. *The American journal of sports medicine.* 2010 Mar;38(3):594–9.
35. Lynch JR, Clinton JM, Dewing CB, Warme WJ, Matsen FA. Treatment of osseous defects associated with anterior shoulder instability. *Journal of shoulder and elbow surgery / American Shoulder and Elbow Surgeons ... [et al.].* 2009;18(2):317–28.
36. Piasecki DP, Verma NN, Romeo AA, Levine WN, Bach BR, Provencher MT. Glenoid bone deficiency in recurrent anterior shoulder instability: diagnosis and management. *The Journal of the American Academy of Orthopaedic Surgeons.* 2009 Aug;17(8):482–93.
37. Provencher MT, Frank RM, Leclere LE, Metzger PD, Ryu JJ, Bernhardson A, et al. The Hill-Sachs lesion: diagnosis, classification, and management. *The Journal of the American Academy of Orthopaedic Surgeons.* 2012 Apr;20(4):242–52.
38. Hill HA, Sachs MD. The Grooved Defect of the Humeral Head: A Frequently Unrecognized Complication of Dislocations of the Shoulder Joint. *Radiology.* 1940;35(6):690 – 700.

39. Taylor DC, Arciero RA. Pathologic changes associated with shoulder dislocations. Arthroscopic and physical examination findings in first-time, traumatic anterior dislocations. *The American journal of sports medicine*. 1997;25(3):306–11.
40. Calandra JJ, Baker CL, Uribe J. The incidence of Hill-Sachs lesions in initial anterior shoulder dislocations. *Arthroscopy*: the journal of arthroscopic & related surgery: official publication of the Arthroscopy Association of North America and the International Arthroscopy Association. 1989 Jan;5(4):254–7.
41. Burkhart SS, De Beer JF, Barth JRH, Cresswell T, Criswell T, Roberts C, et al. Results of modified Latarjet reconstruction in patients with anteroinferior instability and significant bone loss. *Arthroscopy*: the journal of arthroscopic & related surgery: official publication of the Arthroscopy Association of North America and the International Arthroscopy Association. 2007 Oct;23(10):1033–41.
42. Chen AL, Hunt SA, Hawkins RJ, Zuckerman JD. Management of bone loss associated with recurrent anterior glenohumeral instability. *The American journal of sports medicine*. 2005 Jun;33(6):912–25.
43. Bollier MJ, Arciero R. Management of glenoid and humeral bone loss. *Sports medicine and arthroscopy review*. 2010 Sep;18(3):140–8.
44. Bushnell BD, Creighton RA, Herring MM. Bony instability of the shoulder. *Arthroscopy*: the journal of arthroscopic & related surgery: official publication of the Arthroscopy Association of North America and the International Arthroscopy Association. 2008 Sep;24(9):1061–73.
45. Bigliani LU, Newton PM, Steinmann SP, Connor PM, McIlveen SJ. Glenoid rim lesions associated with recurrent anterior dislocation of the shoulder. *The American journal of sports medicine*. 1998;26(1):41–5.
46. Seybold D, Gekle C, Fehmer T, Pennekamp W, Muhr G, Källicke T. [Immobilization in external rotation after primary shoulder dislocation]. *Der Chirurg; Zeitschrift für alle Gebiete der operativen Medizin*. 2006 Sep;77(9):821–6.

47. Scheibel M, Kuke A, Nikulka C, Magosch P, Ziesler O, Schroeder RJ. How long should acute anterior dislocations of the shoulder be immobilized in external rotation? *The American journal of sports medicine*. 2009 Jul;37(7):1309–16.
48. Liavaag S, Stiris MG, Lindland ES, Enger M, Svenningsen S, Brox JI. Do Bankart lesions heal better in shoulders immobilized in external rotation? *Acta orthopaedica*. 2009 Oct;80(5):579–84.
49. Dines DM, Levinson M. The conservative management of the unstable shoulder including rehabilitation. *Clinics in sports medicine*. 1995 Oct;14(4):797–816.
50. Paterson WH, Throckmorton TW, Koester M, Azar FM, Kuhn JE. Position and duration of immobilization after primary anterior shoulder dislocation: a systematic review and meta-analysis of the literature. *The Journal of bone and joint surgery. American volume*. 2010 Dec 15;92(18):2924–33.
51. Kirkley A, Werstine R, Ratjek A, Griffin S. Prospective randomized clinical trial comparing the effectiveness of immediate arthroscopic stabilization versus immobilization and rehabilitation in first traumatic anterior dislocations of the shoulder: Long-term evaluation. *Arthroscopy: The Journal of Arthroscopic & Related Surgery*. 2005 Jan;21(1):55–63.
52. Yamamoto N, Muraki T, Sperling JW, Steinmann SP, Itoi E, Cofield RH, et al. Does the “bumper” created during Bankart repair contribute to shoulder stability? *Journal of shoulder and elbow surgery / American Shoulder and Elbow Surgeons ... [et al.]*. 2012 Sep 27;
53. Grumet RC, Bach BR, Provencher MT. Arthroscopic stabilization for first-time versus recurrent shoulder instability. *Arthroscopy*: the journal of arthroscopic & related surgery: official publication of the Arthroscopy Association of North America and the International Arthroscopy Association. 2010 Feb;26(2):239–48.
54. Owens BD, DeBerardino TM, Nelson BJ, Thurman J, Cameron KL, Taylor DC, et al. Long-term follow-up of acute arthroscopic Bankart repair for initial anterior shoulder dislocations in young athletes. *The American journal of sports medicine*. 2009 Apr;37(4):669–73.

55. Gartsman GM, Roddey TS, Hammerman SM. Arthroscopic treatment of anterior-inferior glenohumeral instability. Two to five-year follow-up. The Journal of bone and joint surgery. American volume. 2000 Jul;82-A(7):991–1003.
56. Koss S, Richmond JC, Woodward JS. Two- to five-year followup of arthroscopic Bankart reconstruction using a suture anchor technique. The American journal of sports medicine. 25(6):809–12.
57. Sperber A, Hamberg P, Karlsson J, Swärd L, Wredmark T. Comparison of an arthroscopic and an open procedure for posttraumatic instability of the shoulder: a prospective, randomized multicenter study. Journal of shoulder and elbow surgery / American Shoulder and Elbow Surgeons ... [et al.]. 2001;10(2):105–8.
58. Harris JD, Gupta AK, Mall NA, Abrams GD, McCormick FM, Cole BJ, et al. Long-term outcomes after bankart shoulder stabilization. Arthroscopy □: the journal of arthroscopic & related surgery □: official publication of the Arthroscopy Association of North America and the International Arthroscopy Association. 2013 May 5;29(5):920–33.
59. Balg F, Boileau P. The instability severity index score. A simple pre-operative score to select patients for arthroscopic or open shoulder stabilisation. The Journal of bone and joint surgery. British volume. 2007 Nov;89(11):1470–7.
60. Greis PE, Scuderi MG, Mohr A, Bachus KN, Burks RT. Glenohumeral articular contact areas and pressures following labral and osseous injury to the anteroinferior quadrant of the glenoid. Journal of shoulder and elbow surgery / American Shoulder and Elbow Surgeons ... [et al.]. 2002;11(5):442–51.
61. Provencher MT, Bhatia S, Ghodadra NS, Grumet RC, Bach BR, Dewing CB, et al. Recurrent shoulder instability: current concepts for evaluation and management of glenoid bone loss. The Journal of bone and joint surgery. American volume. 2010 Dec;92 Suppl 2:133–51.
62. Helfet AJ. Coracoid transplantation for recurring dislocation of the shoulder. The Journal of bone and joint surgery. British volume. 1958;40(B):198–202.
63. Griesser MJ, Harris JD, McCoy BW, Hussain WM, Jones MH, Bishop JY, et al. Complications and re-operations after Bristow-Latarjet shoulder stabilization: a

- systematic review. *Journal of shoulder and elbow surgery / American Shoulder and Elbow Surgeons ... [et al.]*. 2013 Feb;22(2):286–92.
64. Butt U, Charalambous CP. Complications associated with open coracoid transfer procedures for shoulder instability. *Journal of shoulder and elbow surgery / American Shoulder and Elbow Surgeons ... [et al.]*. 2012 Aug;21(8):1110–9.
 65. May VR. A modified Bristow operation for anterior recurrent dislocation of the shoulder. *The Journal of bone and joint surgery. American volume*. 1970 Jul;52(5):1010–6.
 66. Hovelius L, Sandström B, Olofsson A, Svensson O, Rahme H. The effect of capsular repair, bone block healing, and position on the results of the Bristow-Latarjet procedure (study III): long-term follow-up in 319 shoulders. *Journal of shoulder and elbow surgery / American Shoulder and Elbow Surgeons ... [et al.]*. 2012 May;21(5):647–60.
 67. Hovelius L, Akermark C, Albrektsson B, Berg E, Körner L, Lundberg B, et al. Bristow-Latarjet procedure for recurrent anterior dislocation of the shoulder. A 2-5 year follow-up study on the results of 112 cases. *Acta orthopaedica Scandinavica*. 1983 Apr;54(2):284–90.
 68. Latarjet M. [Treatment of recurrent dislocation of the shoulder]. *Lyon chirurgical*. 1954;49(8):994–7.
 69. Young AA, Maia R, Berhouet J, Walch G. Open Latarjet procedure for management of bone loss in anterior instability of the glenohumeral joint. *Journal of shoulder and elbow surgery / American Shoulder and Elbow Surgeons ... [et al.]*. 2011 Mar;20(2 Suppl):S61–9.
 70. Patte D, Debeyre J. Luxations récidivantes de l'épaule. *Encycl Med Chir. Paris-Technique chirurgicale Orthopedie*. 1980;44265(4.4).
 71. Wellmann M, De Ferrari H, Smith T, Petersen W, Siebert CH, Agneskirchner JD, et al. Biomechanical investigation of the stabilization principle of the Latarjet procedure. *Archives of orthopaedic and trauma surgery*. 2012 Mar;132(3):377–86.
 72. Armitage MS, Faber KJ, Drosdowech DS, Litchfield RB, Athwal GS. Humeral head bone defects: remplissage, allograft, and arthroplasty. *The Orthopedic clinics of North America*. 2010 Jul;41(3):417–25.

73. Sekiya JK, Jolly J, Debski RE. The effect of a Hill-Sachs defect on glenohumeral translations, in situ capsular forces, and bony contact forces. *The American journal of sports medicine*. 2012 Feb;40(2):388–94.
74. Sekiya JK, Wickwire AC, Stehle JH, Debski RE. Hill-Sachs defects and repair using osteoarticular allograft transplantation: biomechanical analysis using a joint compression model. *The American journal of sports medicine*. 2009 Dec;37(12):2459–66.
75. Giles JW, Elkinson I, Ferreira LM, Faber KJ, Boons H, Litchfield R, et al. Moderate to large engaging Hill-Sachs defects: an in vitro biomechanical comparison of the remplissage procedure, allograft humeral head reconstruction, and partial resurfacing arthroplasty. *Journal of shoulder and elbow surgery / American Shoulder and Elbow Surgeons ... [et al.]*. 2012 Sep;21(9):1142–51.
76. Connolly JF. Humeral Head Defects Associated with Shoulder Dislocations: Their Diagnostic and Surgical Significance. *Instructional Course Lectures*. 1972;21:42–54.
77. Boileau P, O’Shea K, Vargas P, Pinedo M, Old J, Zumstein M. Anatomical and functional results after arthroscopic Hill-Sachs remplissage. *The Journal of bone and joint surgery. American volume*. 2012 Apr 4;94(7):618–26.
78. Purchase RJ, Wolf EM, Hobgood ER, Pollock ME, Smalley CC. Hill-sachs “remplissage”: an arthroscopic solution for the engaging hill-sachs lesion. *Arthroscopy*: the journal of arthroscopic & related surgery: official publication of the Arthroscopy Association of North America and the International Arthroscopy Association. 2008 Jun;24(6):723–6.
79. Koo SS, Burkhart SS, Ochoa E. Arthroscopic double-pulley remplissage technique for engaging Hill-Sachs lesions in anterior shoulder instability repairs. *Arthroscopy*: the journal of arthroscopic & related surgery: official publication of the Arthroscopy Association of North America and the International Arthroscopy Association. 2009 Nov;25(11):1343–8.
80. Elkinson I, Giles JW, Faber KJ, Boons HW, Ferreira LM, Johnson JA, et al. The effect of the remplissage procedure on shoulder stability and range of motion: an

- in vitro biomechanical assessment. The Journal of bone and joint surgery. American volume. 2012 Jun 6;94(11):1003–12.
81. Wellmann M, Petersen W, Zantop T, Herbort M, Kobbe P, Raschke MJ, et al. Open shoulder repair of osseous glenoid defects: biomechanical effectiveness of the Latarjet procedure versus a contoured structural bone graft. The American journal of sports medicine. 2009 Jan;37(1):87–94.
 82. Schulze-Borges J, Agneskirchner JD, Bobrowitsch E, Patzer T, Struck M, Smith T, et al. Biomechanical comparison of open and arthroscopic Latarjet procedures. Arthroscopy □: the journal of arthroscopic & related surgery □: official publication of the Arthroscopy Association of North America and the International Arthroscopy Association. 2013 Apr 6;29(4):630–7.
 83. Giles JW, Boons HW, Elkinson I, Faber KJ, Ferreira LM, Johnson JA, et al. Does the dynamic sling effect of the Latarjet procedure improve shoulder stability? A biomechanical evaluation. Journal of shoulder and elbow surgery / American Shoulder and Elbow Surgeons ... [et al.]. 2013 Jun 27;22(6):821–7.
 84. Hovelius L, Vikerfors O, Olofsson A, Svensson O, Rahme H. Bristow-Latarjet and Bankart: a comparative study of shoulder stabilization in 185 shoulders during a seventeen-year follow-up. Journal of shoulder and elbow surgery / American Shoulder and Elbow Surgeons ... [et al.]. 2011 Oct;20(7):1095–101.

Chapter 2

2 Bristow versus Latarjet Coracoid Transfer for Recurrent Shoulder Instability with Glenoid Deficiency

Overview:

As introduced earlier, osseous defects of the glenoid greater than 20% of the total width contribute substantially to recurrent shoulder instability. A commonly used treatment to address this deficiency is the utilization of a coracoid transfer. In the literature this has been referred to as a “Bristow-Latarjet” transfer, while historical descriptions of these two procedures have differed. This chapter explores the biomechanical effect of each procedure individually in the treatment of an isolated capsulolabral injury, 15% and 30% glenoid defects to provide a direct comparison of their stabilizing effects. Their effect on range of motion was also monitored and reported here.

(A version of this chapter has been submitted for publication in the Journal of Bone and Joint Surgery, American Volume and is awaiting review.)

2.1 Introduction

In the management of recurrent instability with glenoid deficiency, the selection of the optimal surgical treatment is difficult. Standard soft-tissue Bankart repair has been found to exhibit high failure rates, up to 56% to 67% (1,2). In fact, Itoi *et al.* (2000) found that defects $\geq 21\%$ of the glenoid width significantly decreased the translational force required to produce humeral head subluxation, even following soft-tissue repair (3) and recommended glenoid reconstruction in such cases. Various techniques have been proposed including iliac crest autografting (4,5), allograft reconstruction, and coracoid transfer. Biomechanical investigations by Wellmann *et al.* (2009)(6) and Giles *et al.* (2012) (7), however, have shown that coracoid transfer procedures outperform other surgical reconstructive options due to the dynamic stabilizing ‘sling’ effect, as described by Patte, produced by the repositioned conjoined tendon emanating from the coracoid

process (8). These biomechanical findings, in conjunction with positive clinical results, lend support to the long held belief that coracoid transfer represents one of the best options for instability-related glenoid defects, with some authors proposing its use even in the setting of an isolated capsulolabral tear (9,10).

The coracoid transfer has been described using multiple techniques, with the most common being the Bristow and Latarjet procedures (9,10). While the Bristow procedure consists of transferring only the tip of the coracoid such that the osteotomized surface contacts the glenoid vault (10), the Latarjet procedure transfers the entire horizontal pillar such that the inferior surface of the coracoid contacts the vault (Figure 2-1) (9). Despite the frequent synonymous labeling of these coracoid transfers as the Bristow-Latarjet, they represent different reconstructive procedures and their true equivalence has not been demonstrated.

As such, the purpose of this study was to investigate the effects of the Bristow and the Latarjet procedures to define which technique is biomechanically superior and to provide clarity to the orthopedic community. This was achieved by comparing shoulder stiffness, stability, and range of motion (ROM) when treating progressive levels of instability, beginning with an isolated soft tissue Bankart injury, and subsequent introduction of 15 and 30% bony Bankart lesions. We hypothesized that the incomplete coverage of the anterior glenoid defect with the Bristow coracoid transfer would result in progressively worse stabilization of the shoulder comparing to the Latarjet coracoid transfer as the glenoid defect increased.



Figure 2-1 – The Bristow and Latarjet Coracoid Transfers

Figures illustrating the reconstruction of a 15% anterior glenoid bone defect with the Bristow (left) and Latarjet (right) coracoid transfers. The graft size and orientation for both repairs is consistent with how reconstructions were performed across the three tested defect sizes (0%-isolated capsulolabral injury, 15%, and 30%).

2.2 Materials & Methods

2.2.1 Specimen Preparation and Shoulder Simulator

Eight (8), right-sided, fresh-frozen cadaveric shoulders (74 ± 11 years) were tested after being screened for evidence of rotator cuff deficiency, arthritis, or previous surgery. The humerus was transected ~20cm distal to the inferior articular margin of the humeral head and soft tissues were removed leaving the deltoid insertion, rotator cuff muscles, short and long heads of the biceps, and the glenohumeral joint capsule. A custom shoulder simulator (Figure 2-2) (11,12) was employed. An intra-medullary humeral rod, instrumented with a six degree-of-freedom load cell (Mini45, ATI Industrial Automation, Apex, NC) and optical tracking markers (Optotrak Certus, NDI, Waterloo, ON), was cemented into the humeral shaft, while the opposite end of the rod was connected with the simulator. A transverse axis on the rod was aligned with the anatomic transepicondylar axis to provide a reference for axial rotation. The scapula was cemented onto the simulator in 10° of forward inclination.

The simulator replicated unconstrained glenohumeral motion (7,11–14) (Figure 2-2). Nine muscle groups were loaded along physiologically accurate lines of action using a low friction guide system. Sutures in each group were loaded as follows: the supraspinatus, infraspinatus and teres minor, and subscapularis (7.5N); long head of the biceps, and conjoint tendon (10N); anterior, middle, and posterior deltoids (5N) (6,7,11,13–15). The simulator achieved highly repeatable joint configurations while not influencing glenohumeral kinematics. Abduction, composed of glenohumeral and scapulothoracic rotation, was achieved using a 2:1 ratio using an abduction guide and flexion adjustment plate (16).

Humeral and scapular digitizations were taken with respect to bone affixed optical markers to create an International Society of Biomechanics Euler rotation sequence (17). The functional glenohumeral joint center was determined from kinematic recordings using Woltring's algorithm (18–20). Digitizations at the superior, inferior, anterior and posterior aspects of the glenoid rim were recorded and used to create a separate, glenoid coordinate system coincident with the intact glenohumeral joint center. This coordinate

system was utilized in post-hoc analyses to determine glenohumeral joint translations(17,21).

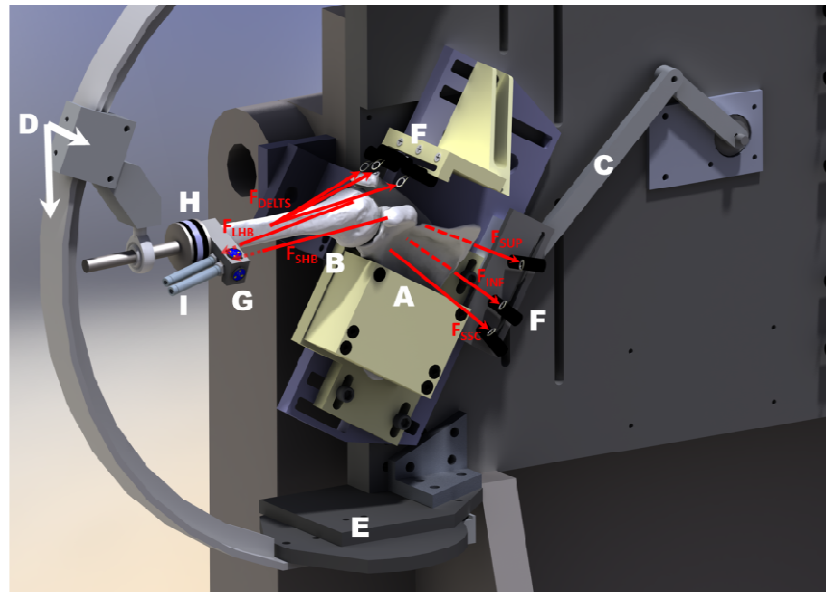


Figure 2-2– In-vitro Shoulder Simulator

This demonstrates a mounted specimen, which has had soft tissues removed for clarity. The overlaid red arrows indicate the loading vectors for each muscle groups (FDELTS – three Deltoid heads, FSUP – Supraspinatus, FINF – Infraspinatus & Teres Minor, FSSC – Subscapularis, FLHB – Long Head of Biceps, FSHB – Conjoint tendon of the Short Head of Biceps). The simulator uses 4 degrees of freedom (DOF) to orient the scapula in a physiologic manner. (A) Potted scapula specimen (with soft tissues omitted for clarity); (B) Humerus (with soft tissues omitted for clarity); (C) Computer controlled scapular elevation mechanism which achieves repeatable positioning; (D) Glenohumeral abduction guide arc and slider; (E) Glenohumeral flexion adjustment plate; (F) Low friction deltoid and rotator cuff guide system which routes cables to pneumatic actuators; (G), Six (6) DOF tracking markers; (H) Cemented humeral rod with interposed 6 DOF load cell; and (I) Miniature pneumatic actuators used to separately load the long head of the biceps and the conjoint group.

2.2.2 Experimental Testing Protocol

The protocol was designed to compare the effects of the Bristow and Latarjet procedures on joint stability and ROM when treating isolated capsulolabral injuries as well as 15 and 30% bony Bankart lesions. In order to achieve the repeated joint access required in this repeated-measures study, an extended lesser tuberosity osteotomy was utilized. A microsagittal saw was used and the osteotomy fixated with two bicortical 1/8” nut-and-bolt constructs. Previous investigations have shown that the osteotomy has no effect on shoulder outcomes (12).

Seven conditions were tested: intact, Bristow and Latarjet repairs with an isolated capsulolabral injury but intact bony glenoid anatomy, followed by Bristow and Latarjet with a 15 and 30% anterior glenoid bone defect. The anterior capsulolabral injury was created by sharply releasing the anteroinferior glenoid labrum and capsule from the inferior glenoid rim. The humerus was then dislocated anteroinferiorly to propagate the injury and ensure instability.

The 15 and 30% bone defects were subsequently created at the anterior aspect of the glenoid rim as described by Saito et al. (2005) who demonstrated that the average anterior bony defect is centered at the “3:01 o’clock” position (22). Yamamoto’s technique for creating simulated glenoid defects was utilized (23). The maximum anteroposterior glenoid width was measured using digital calipers. A line perpendicular to the anteroposterior measurement direction was then created at 15 or 30% of the glenoid width. A microsagittal saw accurately created the defect while care was taken to keep the cut perpendicular to the glenoid face.

Following creation of each respective glenoid defect, a coracoid transfer reconstruction was performed and tested. This repair was then removed and the second transfer procedure was performed. Reconstruction order was randomized and balanced between the Bristow and Latarjet procedures. The Bristow reconstruction was performed as originally described (10) while the Latarjet was performed as described by Walch & Boileau (2000) (24). Both reconstructions require the transfer of a coracoid with an attached conjoint tendon group; however, differing graft sizes are required. Therefore, in

order to test both reconstructions in random order and at multiple defect levels, a size matched coracoid with attached conjoint tendon was harvested from a fresh frozen donor for each specimen tested. For the Bristow reconstruction, the coracoid tip was osteotomized 10mm from its end and, along with the attached conjoint tendon, was transferred through a horizontal subscapularis split at the inferior 1/3rd superior 2/3rd junction to the anterior glenoid. The osteotomized surface of the coracoid tip was then rigidly fixed to the glenoid vault using one 3.75mm bicortical screw inserted along the grafts long axis (Figure 2-1). For the Latarjet reconstruction, the coracoid was osteotomized at its angle, or 'elbow', between the insertion of the pectoralis minor and the attachment of the coracoclavicular ligaments. This was then transferred along with the conjoint tendon to the anterior glenoid again through the subscapularis split. The inferior surface of the coracoid was decorticated and rigidly fixed to the anterior glenoid vault using two 3.75mm bicortical screws (Figure 2-1). Capsular repair, normally performed incorporating a segment of the coracoacromial ligament, was not feasible as part of the testing protocol.

For each of these reconstructions, the coracoid was removed following testing in order to allow the other reconstruction to be fixated and tested or in order to create the next defect level. Care was taken to utilize the same drill holes for securing each subsequent reconstruction and screws were passed through the posterior cortex of the glenoid neck. No loss of fixation was observed at any point during testing.

During testing, the conjoint tendon of the short head of the biceps and coracobrachialis was loaded in order to replicate the dynamic 'sling' effect (7,25). The tendon was loaded by suturing the proximal musculotendinous junction and replicating its natural line of action before connecting it to a pneumatic actuator (Bimba, University Park, IL) mounted to the humeral rod (Figure 2-2)(11). The tendon was accurately tensioned, throughout the tested ROM, to a magnitude of 10N as this force has been shown to initiate the dynamic sling effect of the conjoint tendon, where the tendon assumes a position along the anterior aspect of the glenohumeral joint, largely when the arm is brought into abduction, and provides a resistive force to anterior humeral head translation (11).

2.2.3 Stability and Range of Motion

Glenohumeral joint stability and ROM were measured in two joint configurations: (1) adduction (Add: 0° of flexion and 0° of abduction) and (2) abduction (Abd: 0° of flexion and 60° of glenohumeral abduction with 30° of scapulothoracic elevation). Stability was quantified using glenohumeral joint stiffness (N/mm) and the occurrence of humeral head dislocation. Stiffness was calculated by manually applying an antero-inferiorly directed quasi-static load of up to 80 N and dividing it by the magnitude of humeral translation relative to the glenoid. Eighty Newtons was chosen as the maximum load for this test through pilot testing in which a load cell was used to determine the average maximum force, over multiple trials, applied by an experienced shoulder surgeon (GSA) performing a standard drawer test. The drawer test involves holding the arm in 90° of abduction and 60° of external rotation and passively applying an extension force until soft tissue resistance is felt. Maximum humeral translation was defined as the magnitude of displacement at the time of glenohumeral dislocation or at maximum force application if a dislocation did not occur. Dislocation, which was considered to have occurred when the apex of the humeral head passed the intact/reconstructed glenoid rim, was assessed visually during testing and confirmed using optical tracking data during analysis. Stiffness was evaluated in both neutral rotation (NR) (defined as epicondylar axis parallel to the coronal body plane) and 60° of external rotation (ER). A load cell (Model 34 Precision Miniature, Honeywell, Golden Valley, MN) provided live feedback of the applied load. Glenohumeral kinematics and joint forces were recorded throughout each test using the optical trackers and load cell described above.

Two modes of dislocation were assessed. Dislocation was first assessed with the shoulder placed in 90° of composite abduction and 60° of glenohumeral external rotation, commonly termed the 'position of apprehension'. The assessment involved gradually moving the humerus into horizontal extension until reaching a soft tissue endpoint consistent with a clinical examination, or until dislocation occurred. This provided a qualitative assessment of the occurrence of dislocation and a quantitative measure of horizontal extension ROM posterior to the scapular plane. The second assessment involved identifying dislocation during the above described joint stiffness test with the

shoulder in abduction and external rotation. This assessment replicated dislocation during a clinical drawer test.

Internal-external rotation ROM was determined by rotating the humerus in each direction until a predefined resisting torque criterion of ± 0.8 Nm was met. The criterion was selected as it represented the average of repeated blinded trials on a pilot specimen, by an orthopedic surgeon, rotating the humerus until reaching a resistance consistent with clinical evaluation.

2.2.4 Outcome Variables & Statistical Analyses

Stability was quantified in terms of glenohumeral joint stiffness (N/mm) and dislocation (dislocation or no dislocation). ROM is reported as the magnitude in degrees traversed by the humerus. For internal-external rotation this value was taken as the rotation from the maximum internal to the maximum external rotation position while horizontal extension ROM was quantified as the total degrees the humerus was rotated about the scapula's superior axis, posterior to the scapular plane.

Two-way repeated-measures Analyses of Variance (RM-ANOVAs) were performed for each outcome variable, to assess the main effects and any interaction of repair technique (Bristow vs. Latarjet) across the three defect levels. In the case of any interactions, follow-up post-hoc tests were performed. The results from intact testing could not be included in the Two-way RM-ANOVAs as they were not a repeated measurement and thus a series of One-way RM-ANOVAs were performed in order to allow comparisons between the reconstructions and the intact state. These One-way RM-ANOVAs and associated pair-wise comparisons were carried out for all outcome variables at each tested shoulder configuration and defect level. This resulted in 12 One-way RM-ANOVAs for joint stiffness and 9 across the three range of motion tests. Each analysis consisted of three conditions: intact, Bristow, and Latarjet. Significance was set to $p < 0.05$. A Priori power analyses were performed with data drawn from a similar, previously published study of the Latarjet. It was found that 8 specimens were sufficient to achieve a minimum power of 80% in detecting clinically relevant differences in the

range of 10° for ROM and 30% for joint stiffness. Joint dislocation was considered to be a secondary outcome measure and was not part of our statistical power analysis.

2.3 Results

(all statistics are reported with their respective standard deviations throughout the thesis)

2.3.1 Joint Stiffness and Stability

Comparing the Bristow and Latarjet procedures across the three defect levels using a Two-way RM-ANOVA demonstrated that there were no interaction effects between changes in repair technique and defect size ($p \geq 0.189$) except with the arm in Add-NR ($p=0.014$). In this case, post-hoc tests demonstrated that the Bristow produced significantly less stiffness than the Latarjet for the 15% and 30% defect (4.7 ± 1.1 N/mm, $p=0.004$ & 5.6 ± 1.9 N/mm, $p=0.021$, respectively) but not the 0% (isolated capsulolabral) defect (2.0 ± 1.2 N/mm, $p=0.156$) (Figure 2-3). The main effect of reconstruction type was found to be significant for all joint configurations, with the Latarjet resulting in significantly greater stiffness than the Bristow across all three glenoid defect levels (Add-NR: 4.1 ± 1.3 N/mm, $p=0.018$; Add-ER: 4.9 ± 1.3 N/mm, $p=0.007$; Abd-NR: 1.8 ± 0.5 N/mm, $p=0.012$; Abd-ER: 1.9 ± 0.4 N/mm, $p=0.003$).

Subsequent one-way RM-ANOVAs for each joint configuration at each of the three defect levels (Figures 2-3 & Figure 2-4) further illustrate the significance of the above trends. The Bristow procedure resulted in joint stiffness values that were consistently less than the intact and the Latarjet. Decreases in stiffness between the Bristow and intact shoulder were significant at all defect levels with the joint in adduction ($p \leq 0.040$) and for the 15 and 30% defects with the shoulder in Abd-ER ($p \leq 0.002$). In contrast, the Latarjet produced stiffness values similar to intact and only differed significantly in one case -- with the shoulder in Add-NR, following reconstruction of a 0% defect, where stiffness was significantly less than in the intact shoulder (3.9 ± 1.1 N/mm, $p \leq 0.026$).

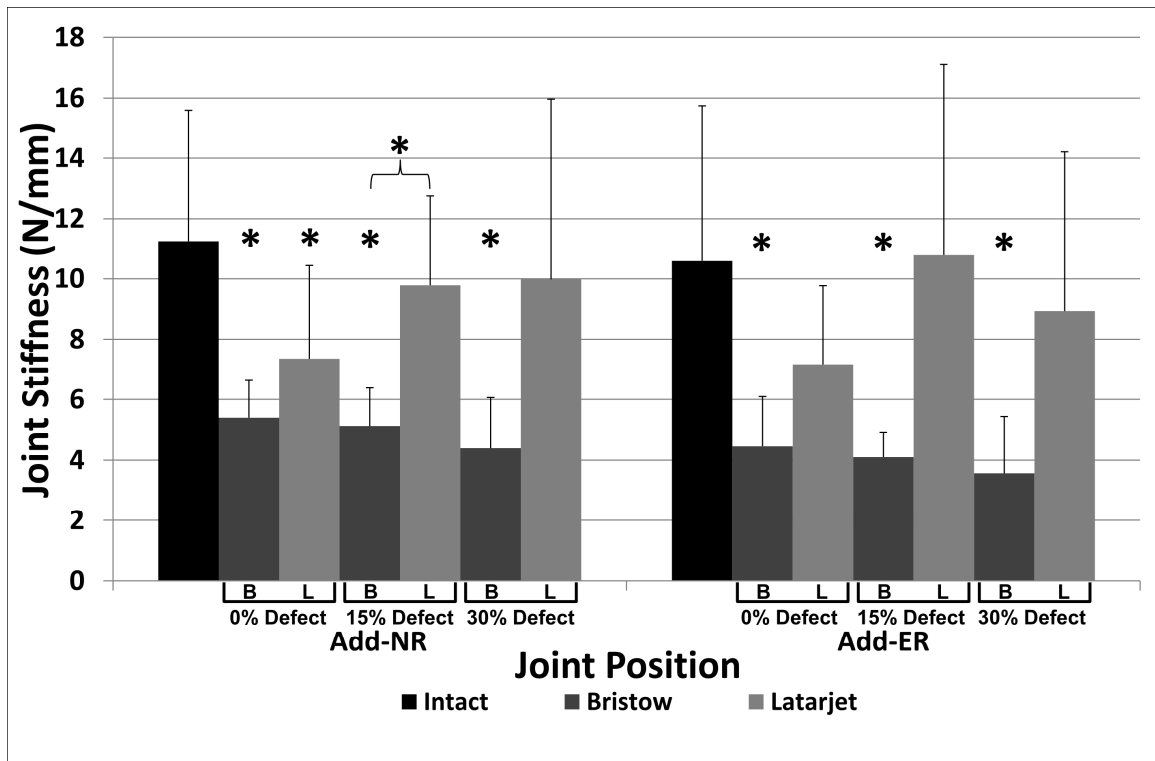


Figure 2-3. Anterior Glenohumeral Joint Stiffness in Adduction and Neutral or External Rotation.

Joint stiffness \pm 1 SD (in N/mm) in response to an anteriorly directed force for each reconstructed condition reported with the arm in adduction and neutral rotation (left) and adduction and external rotation (right). Note that 'B' and 'L' denote Bristow and Latarjet reconstructions, respectively. Additionally, any testing state marked with a * symbol represents a significant difference in comparison to the intact state. Statistically significant differences between the reconstruction techniques is denoted by a parenthesis and *.

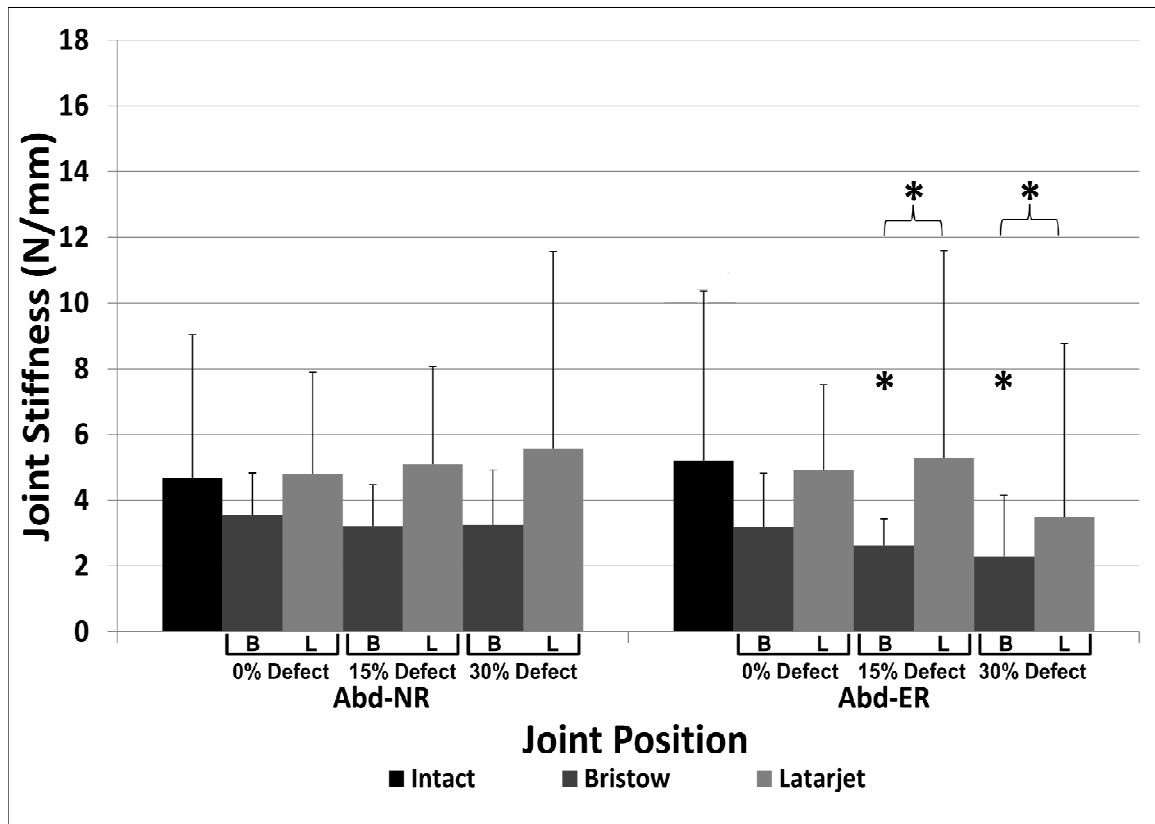


Figure 2-4. Anterior Glenohumeral Joint Stiffness in Abduction and Neutral or External Rotation.

Joint stiffness \pm 1 SD (in N/mm) in response to an anteriorly directed force for each reconstructed condition reported with the arm in adduction and neutral rotation (left) and adduction and external rotation (right). Note that 'B' and 'L' denote Bristow and Latarjet reconstructions, respectively. Additionally, any testing state marked with a * symbol represents a significant difference in comparison to the intact state. Statistically significant differences between the reconstruction techniques is denoted by a parenthesis and *.

One-way RM-ANOVAs also evaluated differences between the Bristow and Latarjet procedures and demonstrated that the greater joint stiffness seen following the Latarjet was significant for the 15% defect in Add-NR ($4.7 \pm 1.1 \text{ N/mm}$, $p \leq 0.012$) and the 15 & 30% defects in Abd-ER ($2.7 \pm 0.7 \text{ N/mm}$, $p \leq 0.026$ & $1.2 \pm 0.3 \text{ N/mm}$, $p \leq 0.017$). While not statistically significant, the Latarjet increased stiffness for the 30% defect in Add-NR ($5.6 \pm 1.9 \text{ N/mm}$, $p \leq 0.062$) and the 15 & 30% defects in Add-ER to near-significant levels ($6.7 \pm 2.3 \text{ N/mm}$, $p \leq 0.064$ & $5.4 \pm 1.8 \text{ N/mm}$, $p \leq 0.056$).

Stability, quantified in terms of incidents of joint dislocation, was assessed during horizontal extension testing and it was found that the Bristow permitted dislocation in 4 of 8 and 6 of 8 specimens for the 15 and 30% defects respectively, while again, the Latarjet permitted only one dislocation in each case (Table 2-1). Non-parametric McNemar tests for dislocations during extension indicated that the difference in the incidence was not significant for the 15% defect ($p=0.250$) but did approach significance for the 30% defect ($p=0.063$). Dislocations were also recorded during stiffness testing in abduction-external rotation, which replicates the clinical drawer test. This assessment found that the Bristow permitted dislocation in 6 of 8 specimens when treating a 15% glenoid defect and 4 of 8 specimens when treating a 30% defect while the Latarjet permitted only one dislocation at each defect level. In contrast to the extension results, the McNemar test revealed that there was no significant difference for the 30% defect ($p=0.125$) but the incidence of dislocation during stiffness testing did approach significance for the 15% defect ($p=0.063$).

Defect Size	Drawer Test			Extension		
	0%	15%	30%	0%	15%	30%
Bristow	0	6	4	0	4	6
Latarjet	0	1	1	0	1	1

Table 2-1. Incidents of Glenohumeral Joint Dislocation during Two Stability Tests.

Joint stability quantified by the number of dislocations that occurred in each testing condition. Each of the above numbers represents the raw number of dislocations that occurred when testing all 8 specimens for each condition and test. The 'Drawer Test' column indicates dislocations that occurred following application of an anteriorly directed force with the arm in the position of apprehension (abduction & external rotation) following reconstruction of a 0, 15, or 30% defect. The 'Extension' column represents dislocations that occurred while passively extending the humerus from an initial position of abduction and external rotation in the scapular plane with no anteriorly directed force.

2.3.2 Range of Motion

Two-way RM-ANOVAs for ROM in adduction and abduction indicated that there were no interaction effects between changes in repair type and defect size ($p \geq 0.333$). No significant main effects were found in internal-external rotation ROM during adduction across either the reconstruction type or defect level ($p \geq 0.288$) (Figure 2-5). In abduction, there were also no significant main effects in internal-external rotation ROM across all testing conditions ($p \geq 0.452$). However, one-way RM-ANOVAs at each defect level demonstrated that there were statistical differences between the reconstructions, and when comparing the reconstruction to the intact state. Specifically, both the Bristow and Latarjet significantly reduced ROM compared to the intact condition with differences across the three defect levels ranging between $12.5\text{-}20.6^\circ$ ($p \leq 0.045$) for the Bristow and $19.8\text{-}20.2^\circ$ ($p \leq 0.033$) for the Latarjet. In contrast, the only difference between the two reconstructions was a significant reduction following the Latarjet compared to the Bristow for the 0% defect ($7.7 \pm 2.2^\circ$, $p = 0.033$).

During horizontal extension with the arm in abduction-external rotation, there was no significant interaction effect or main effect in ROM across reconstruction type or defect level ($p \geq 0.298$). There were also no trends from one-way RM-ANOVAs comparing the reconstructions to the intact state for the three defect levels (Figure 2-5).

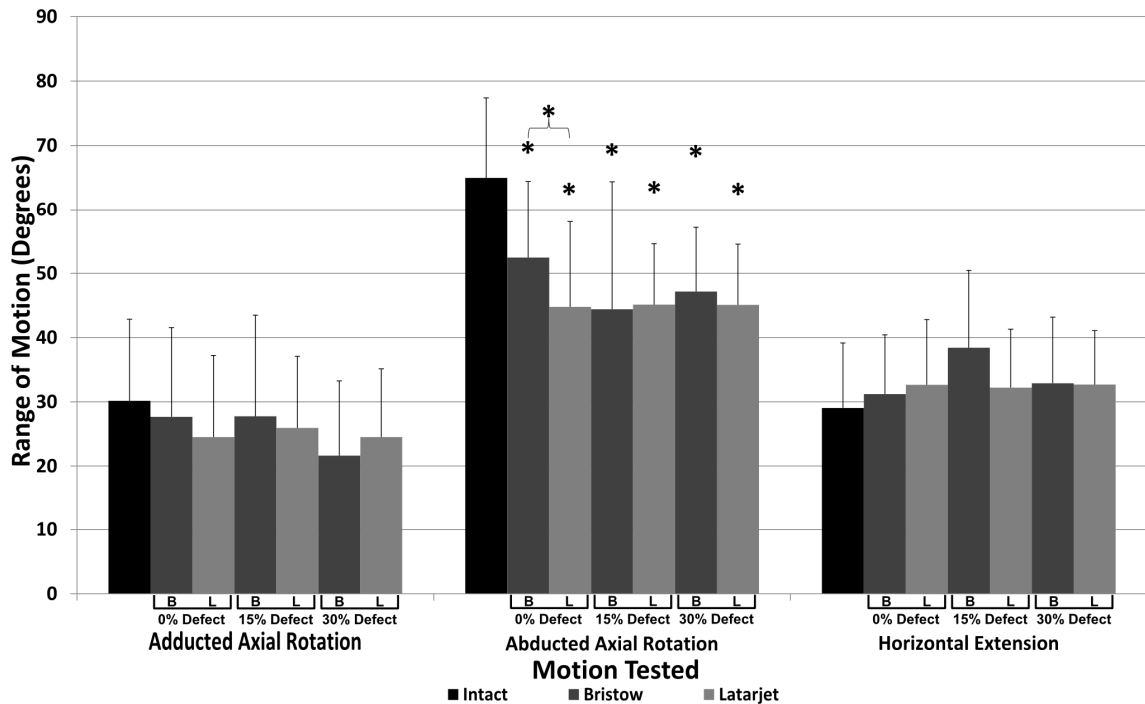


Figure 2-5. Axial Rotation in Adduction and Abduction, and Horizontal Extension in Abduction.

Glennohumeral axial rotation testing results, reporting the arc of motion for internal and external rotation ± 1 SD tested in both the adducted (left) and abducted (middle) positions. Also, horizontal extension range of motion reported (right) with the arm tested in abduction and external rotation. Note that 'B' and 'L' denote Bristow and Latarjet reconstructions, respectively. Additionally, any testing state marked with a * symbol represents a significant difference to the intact state. Statistically significant differences between the reconstruction techniques is denoted by a parenthesis and *.

2.4 Discussion

Recurrent glenohumeral instability associated with glenoid insufficiency is a common clinical entity in general orthopedic practice. For glenoid defects beyond those manageable with isolated soft-tissue Bankart repair, coracoid transfer is becoming a more appealing surgical option. This is frequently referred to as the 'Bristow-Latarjet' coracoid transfer, under the assumption the two procedures are equivalent; however, there is a lack of evidence to support this synonymous labeling. Therefore, the purpose of this investigation was to clarify the biomechanical effects of the Bristow and Latarjet techniques and define which is optimal.

Glenohumeral joint stiffness, the resistance of the joint to anterior translation, was assessed in similar fashion to the clinical drawer test, which provided quantitative information about joint kinematics. In all joint configurations and with any glenoid defect, the Latarjet yielded greater stiffness than the Bristow procedure, ranging from +30 to +90%. Additionally, the Bristow yielded stiffness markedly less than the intact condition (-27 to -99%) while the Latarjet was able to restore stiffness close to intact in most conditions (-16 to +17%). Comparing to the intact, the reduced stiffness following the Bristow was statistically significant in 8 of 12 joint conditions, while following the Latarjet only 1 joint condition was significantly different. Comparing between the two techniques, differences approached and surpassed significance in 6 of 12 comparisons with the Latarjet outperforming the Bristow in the 15 and 30% glenoid defect states following reconstruction. Abduction with neutral rotation proved to be the only joint configuration where no difference was significant. These findings indicate that the Latarjet consistently outperformed the Bristow in terms of restoring joint stiffness and that the disparity between the two techniques increases with increasing anterior glenoid deficiency.

Finally, it was found that for all shoulder configurations, stiffness following Latarjet reconstruction actually increased between the 0 and 15% defect and in 2 of 4 cases between the 15 and 30% defect. We believe that this somewhat unexpected trend can be attributed to the progressive posterior positioning of the conjoint tendon origin as

the coracoid graft is fixated to sequentially larger defects. This increases tension in the conjoint tendon, causing it to wrap under the humeral head more completely and strengthen the dynamic sling effect, biomechanically confirmed in previous literature(7,15).

In the condition of an isolated capsulolabral injury without glenoid bone loss, the Bristow and Latarjet procedures were equivalent in their ability to prevent dislocation. However, in conditions of glenoid bone loss, only one specimen dislocated following either instability test (Drawer Test and Horizontal Extension) at any defect level for the Latarjet reconstruction, while the Bristow permitted dislocation in 50-75% of specimens. It is important to note that the non-parametric McNemar test used to assess dislocation only approached significant differences for the 30% defect during extension and the 15% defect during stiffness testing; however, this can be attributed to the relatively lower power of this type of non-parametric test compared to more common parametric tests. Further analysis indicated that if the relative incidence of dislocation between the Bristow and Latarjet procedures were to stay constant, a 50% increase in specimen count would result in significant differences with 80% power for all comparisons.

Shoulder ROM was assessed for multiple joint configurations and motions in order to determine what, if any, affect the two stabilization procedures produced. Internal-external rotation ROM was first assessed in full adduction and it was found that the Bristow and Latarjet had variable effects between defect levels although no trends were observed and no differences were identified compared to the intact condition (-8 to -32%). In contrast, the effects of the two reconstructions were quite consistent across all conditions during abducted ROM testing, significantly reducing the internal-external rotation arc compared to the intact state (-31 to -37%) with the exception of the Bristow reconstruction with an isolated capsulolabral injury (-21%). In addition, the reduced motion following the Bristow (52.4°) and Latarjet reconstructions (44.8°) in the isolated capsulolabral injury condition also reached statistical significance, indicating that both reconstructions do have a restrictive effect on the shoulder's abducted axial rotation motion. Also, the horizontal extension ROM consistently increased across all reconstructions (mean: +4.3±2.6°) but was not statistically different from intact.

Therefore, neither reconstruction had an effect on the shoulder's horizontal extension ROM.

Limitations to this study included the use of cadaveric specimens, the need to utilize a donor coracoid for one repair, and the inability to test the unrepaired defect state prior to testing the reconstructions. The use of cadaveric specimens is an inherent limitation to this study and means that all results represent time zero biomechanics without accounting for healing effects such as soft tissue relaxation over time. Despite this limitation, this study provides an important comparison of the two techniques. The use of a size matched coracoid donor with attached conjoint tendon is a limitation as it is possible that the donor graft may not have exactly matched the true coracoid; however, the use of the graft was randomized and balanced between specimens and thus any differences should affect both reconstructions equally. The use of successive glenoid defects precluded testing of the unrepaired state at each defect level as the specimen's coracoid was removed at the first defect level; however, the primary goal of the study was to make comparisons to intact and between reconstructions and thus collection of this data was not imperative.

The findings herein have supported our hypothesis and clarified the effects of the Bristow and the Latarjet coracoid transfers, demonstrating that these two reconstructions are not equivalent and should therefore not be considered interchangeable when used in the clinical setting to treat complex anterior shoulder instability. Comparison has shown that the Latarjet has a greater ability to restore glenohumeral joint stiffness and prevent joint dislocation. This restoration of joint stiffness will also help to normalize joint kinematics and kinetics by maintaining the joint in a well-reduced configuration, thus preventing excessive coracoid graft loading.

Evaluation of the effects on ROM has demonstrated that abducted axial rotation was significantly limited by both reconstructions. While this restriction is worrisome from a patient satisfaction point of view, it may prevent the joint from reaching the position of apprehension, which could still subjectively cause feelings of instability despite improved stability. Additionally, the Bristow procedure produces this restriction

without effectively restoring intact joint stiffness and thus carries the disadvantages of the Latarjet—motion restriction—without its benefits—joint stabilization. Further studies are required to determine if this restriction is clinically significant, and whether it remains over time or decreases with soft-tissue attenuation.

2.5 Conclusion

In conclusion, in the setting of anterior shoulder instability without glenoid bone loss, the Bristow and Latarjet procedures are essentially equivalent in their ability to stabilize the shoulder. However, the Latarjet results in a significant restriction of rotational range of motion, while the Bristow does not, indicating that the Bristow may be the preferred coracoid transfer procedure in conditions of intact glenoid bone. In the setting of substantial glenoid deficiency the Latarjet procedure is superior to the Bristow in its ability to restore joint stability and, therefore, in terms of its biomechanical efficacy, may represent a preferable treatment option among coracoid transfer procedures.

2.6 References

1. Burkhart SS, De Beer JF. Traumatic glenohumeral bone defects and their relationship to failure of arthroscopic Bankart repairs: significance of the inverted-pear glenoid and the humeral engaging Hill-Sachs lesion. *Arthroscopy*: the journal of arthroscopic & related surgery: official publication of the Arthroscopy Association of North America and the International Arthroscopy Association. 2000 Oct;16(7):677–94.
2. Tauber M, Resch H, Forstner R, Raffl M, Schauer J. Reasons for failure after surgical repair of anterior shoulder instability. *Journal of shoulder and elbow surgery / American Shoulder and Elbow Surgeons ... [et al.]*. 13(3):279–85.
3. Itoi E, Lee SB, Berglund LJ, Berge LL, An KN. The effect of a glenoid defect on anteroinferior stability of the shoulder after Bankart repair: a cadaveric study. *The Journal of bone and joint surgery. American volume*. 2000 Jan;82(1):35–46.
4. Montgomery WH, Wahl M, Hettrich C, Itoi E, Lippitt SB, Matsen FA. Anteroinferior bone-grafting can restore stability in osseous glenoid defects. *The Journal of bone and joint surgery. American volume*. 2005 Sep;87(9):1972–7.
5. Warner JJP, Gill TJ, O'hollerhan JD, Pathare N, Millett PJ. Anatomical glenoid reconstruction for recurrent anterior glenohumeral instability with glenoid deficiency using an autogenous tricortical iliac crest bone graft. *The American journal of sports medicine*. 2006 Feb;34(2):205–12.
6. Wellmann M, Petersen W, Zantop T, Herbort M, Kobbe P, Raschke MJ, et al. Open shoulder repair of osseous glenoid defects: biomechanical effectiveness of the Latarjet procedure versus a contoured structural bone graft. *The American journal of sports medicine*. 2009 Jan;37(1):87–94.
7. Giles JW, Boons HW, Elkinson I, Faber KJ, Ferreira LM, Johnson JA, et al. Does the dynamic sling effect of the Latarjet procedure improve shoulder stability? A biomechanical evaluation. *Journal of shoulder and elbow surgery / American Shoulder and Elbow Surgeons ... [et al.]*. 2013 Jun 27;22(6):821–7.

8. Patte D, Debeyre J. Luxations récidivantes de l'épaule. *Encycl Med Chir. Paris-Technique chirurgicale Orthopedie*. 1980;44265(4.4).
9. Latarjet M. [Treatment of recurrent dislocation of the shoulder]. *Lyon chirurgical*. 1954;49(8):994–7.
10. Helfet AJ. Coracoid transplantation for recurring dislocation of the shoulder. *The Journal of bone and joint surgery. British volume*. 1958;40(B):198–202.
11. Giles JW, Boons HW, Ferreira LM, Johnson JA, Athwal GS. The effect of the conjoined tendon of the short head of the biceps and coracobrachialis on shoulder stability and kinematics during in-vitro simulation. *Journal of biomechanics*. 2011 Apr 7;44(6):1192–5.
12. Giles JW, Elkinson I, Ferreira LM, Faber KJ, Boons H, Litchfield R, et al. Moderate to large engaging Hill-Sachs defects: an in vitro biomechanical comparison of the remplissage procedure, allograft humeral head reconstruction, and partial resurfacing arthroplasty. *Journal of shoulder and elbow surgery / American Shoulder and Elbow Surgeons ... [et al.]*. 2012 Sep;21(9):1142–51.
13. Elkinson I, Giles JW, Faber KJ, Boons HW, Ferreira LM, Johnson JA, et al. The effect of the remplissage procedure on shoulder stability and range of motion: an in vitro biomechanical assessment. *The Journal of bone and joint surgery. American volume*. 2012 Jun 6;94(11):1003–12.
14. Elkinson I, Giles JW, Boons HW, Faber KJ, Ferreira LM, Johnson JA, et al. The shoulder remplissage procedure for Hill-Sachs defects: does technique matter? *Journal of shoulder and elbow surgery / American Shoulder and Elbow Surgeons ... [et al.]*. 2013 Jun 26;22(6):835–41.
15. Wellmann M, De Ferrari H, Smith T, Petersen W, Siebert CH, Agneskirchner JD, et al. Biomechanical investigation of the stabilization principle of the Latarjet procedure. *Archives of orthopaedic and trauma surgery*. 2012 Mar;132(3):377–86.
16. McQuade KJ, Smidt GL. Dynamic scapulohumeral rhythm: the effects of external resistance during elevation of the arm in the scapular plane. *The Journal of orthopaedic and sports physical therapy*. 1998 Feb;27(2):125–33.
17. Wu G, Van der Helm FCT, Veeger HEJD, Makhsous M, Van Roy P, Anglin C, et al. ISB recommendation on definitions of joint coordinate systems of various joints

- for the reporting of human joint motion--Part II: shoulder, elbow, wrist and hand. *Journal of biomechanics*. 2005 May;38(5):981–92.
18. Ehrig RM, Taylor WR, Duda GN, Heller MO. A survey of formal methods for determining the centre of rotation of ball joints. *Journal of biomechanics*. 2006 Jan;39(15):2798–809.
 19. Monnet T, Desailly E, Begon M, Vallée C, Lacouture P. Comparison of the SCoRE and HA methods for locating in vivo the glenohumeral joint centre. *Journal of biomechanics*. 2007 Jan;40(15):3487–92.
 20. Woltring HJ. Data Processing and error analysis. In: Berne P, Capozzo A, editors. *Biomechanics of Human Movement, Applications in Rehabilitation, Sport and Ergonomics*. Worthington, OH: Berlec Corporation; 1990. p. 203–37.
 21. Woltring HJ. Estimation of the trajectory of the instantaneous centre of rotation in planar biokinematics. *Journal of biomechanics*. 1990 Jan;23(12):1273–4.
 22. Saito H, Itoi E, Sugaya H, Minagawa H, Yamamoto N, Tuoheti Y. Location of the glenoid defect in shoulders with recurrent anterior dislocation. *The American journal of sports medicine*. 2005 Jun;33(6):889–93.
 23. Yamamoto N, Itoi E, Abe H, Kikuchi K, Seki N, Minagawa H, et al. Effect of an anterior glenoid defect on anterior shoulder stability: a cadaveric study. *The American journal of sports medicine*. 2009 May;37(5):949–54.
 24. Walch G, Boileau P. Latarjet-Bristow Procedure for Recurrent Anterior Instability. *Techniques in Shoulder & Elbow Surgery*. 2000;1(4):256–61.
 25. Burkhart SS, De Beer JF, Barth JRH, Cresswell T, Criswell T, Roberts C, et al. Results of modified Latarjet reconstruction in patients with anteroinferior instability and significant bone loss. *Arthroscopy*: the journal of arthroscopic & related surgery: official publication of the Arthroscopy Association of North America and the International Arthroscopy Association. 2007 Oct;23(10):1033–41.

Chapter 3

3 Remplissage versus Latarjet Coracoid Transfer for Hill-Sachs defects: A Biomechanical Comparison

Overview

In addition to glenoid defects, osseous defects of the humeral head also serve to propagate further episodes of shoulder instability. Similarly, once they reach a size of greater than 20% of the overall humeral head width, surgical treatment is recommended. There are generally two major classes of procedures to address these defects: anatomic reconstruction, which aims to recreate the humeral head; or non-anatomic procedures, that attempt to limit engagement via alternate means. This chapter explores the biomechanical effects of two non-anatomic procedures, the remplissage and the Latarjet coracoid transfer, in the management of a 25% engaging Hill-Sachs defect.

(A version of this chapter has been submitted for publication in Clinical Orthopaedics and Related Research and is awaiting review.)

3.1 Introduction

In addition to capsuloligamentous disruptions and glenoid defects, recurrent instability is frequently associated with impaction fractures of the posterosuperior humeral head (Hill-Sachs defects). Hill-Sachs (HS) defects differ in size and orientation, producing variable effects on subsequent shoulder instability. In the same manner as glenoid defects, untreated humeral head defects have also been found to predispose to recurrent instability when retrospectively reviewing success rates following Bankart stabilization (1,2). Classically, it is believed that when a lesion represents >20% of the diameter of the humeral head, it reduces the arc of motion available before the lesion ‘engages’ the anterior rim of the glenoid in abduction and external rotation, facilitating an anterior dislocation (3). Treating the associated HS defect, however, can dramatically reduce recurrence rates from as high as 67%, down to 2 - 5% (4,5), although the exact technique for managing these defects remains controversial.

Described procedures have ranged from allograft humeral head reconstruction, to rotational proximal humeral osteotomies, osteochondral transplant or even humeral head replacement (6). Two procedures garnering interest in recent years – the remplissage procedure and the Latarjet coracoid transfer – are aimed at limiting defect engagement and subsequent glenohumeral dislocation.

As described earlier, remplissage involves posterior capsulodesis and infraspinatus tenodesis into the HS defect, converting the intra-articular impaction defect into an extra-articular defect and preventing engagement with the anterior glenoid rim through a soft tissue bumper. Initially success rates were reported to be around 93% among the describing author’s treatment group (7).

The Latarjet coracoid transfer extends the glenoid arc length, providing not only additional bony support to resist humeral axial loads, but also a restrictive soft tissue “sling effect” that helps resist anterior translation of the humeral head (4,8,9). By increasing the glenoid arc length, and subsequently the distance to the reconstructed anterior glenoid rim, greater external rotation is allowed before HS defect engagement, reducing the incidence of glenohumeral dislocation (4).

The purpose of our study was to perform a biomechanical comparison of the remplissage procedure to the traditional Latarjet coracoid transfer for management of an engaging Hill-Sachs defect. Glenohumeral joint stiffness, which was defined as resistance of anterior humeral head translation to an applied force, and internal-external range of motion were the primary outcomes measured. A secondary outcome measured included joint stability, monitored with the incidence of dislocation. We hypothesized that shoulders treated with a Latarjet coracoid transfer would have greater stability and a preserved range of motion relative to shoulders treated with the remplissage procedure.

3.2 Materials & Methods

3.2.1 Specimen Preparation

Eight, right-sided, fresh-frozen cadaveric shoulder specimens (74 ± 11 years) were used for this study. A power analysis was utilized to determine the minimum number of

specimens required to attain at least 80% power for stiffness and range of motion, which was calculated to be eight specimens. Incidence of dislocation was not part of our power analysis, but rather was a secondary outcome measure. Prior to specimen preparation, CT scans were obtained and reviewed to ensure specimen quality was satisfactory for testing. Any evidence of trauma, rotator cuff tears, arthritic changes of the glenohumeral joint, or cystic changes in the humeral head were used as exclusion criteria. Each specimen was allowed to thaw for 24 hours before preparation. Soft tissues were appropriately removed, in order to leave the origin and insertions of the deltoid muscle, rotator cuff muscles, both heads of the biceps and glenohumeral capsule intact. Number 2 Ethibond sutures (Ethicon Inc., Somerville, NJ) were placed into the tendons of the three heads of the deltoid, supraspinatus, infraspinatus, teres minor, subscapularis, the conjoint tendon and the long head of the biceps to facilitate the application of physiologic loads (10–15).

As described in Chapter 2, the proximal portion of a steel-intramedullary rod fitted with a six degrees-of-freedom (DOF) load cell (Mini45, ATI Industrial Automation, Apex, NC) was cemented into the humeral canal such that a transverse reference axis on the rod was aligned with the anatomic epicondylar axis as described by Wellmann et al. (2011). It was then possible to connect the specimen to the shoulder simulator during testing via the distal end of the rod.

3.2.2 Shoulder Simulator

(The shoulder simulator employed in this study is similar to the system described in Chapter 2. The description to follow, while partially redundant, is included to be consistent with the publication version of this chapter.)

In order to mount the specimen onto the simulator the soft tissues on the inferior portion of the scapula were removed and the scapula was cemented into a scapular pot in 10° of forward inclination. The humeral intramedullary rod was then connected to the simulator via a spherical bearing, which allowed the specimen to be positioned

throughout its range of motion while permitting unaffected glenohumeral kinematics. It was then possible to test the specimen in repeatable glenohumeral and scapulothoracic orientations through adjustment of the custom stability testing apparatus. The sutured tendons were passed through alignment guides to ensure physiologic force vectors and connected to computer controlled pneumatic actuators (Airpot Co., Norwalk, CT, USA). The conjoint tendon was loaded with 10N of tension and the supraspinatus, subscapularis, and the combination of the infraspinatus and teres minor were each loaded with 7.5 N (10–15). The anterior, lateral and posterior heads of the deltoid muscle were each loaded with 5N (10,11,14,16)

Optical markers (Optotrak Certus, Northern Digital, Waterloo, ON, CA) were mounted on the scapula and humerus to continuously monitor glenohumeral kinematics including joint translations and rotations during the testing protocol. Additionally, a clinically-relevant co-ordinate system was created using a series of points digitized on the humerus and scapula.

3.2.3 Surgical Protocol

This protocol was designed to test the effects of the remplissage and the Latarjet procedures on shoulder stability and motion in the setting of a moderate (25%) Hill-Sachs defect. A lesser tuberosity osteotomy (LTO) was performed to allow repetitive access to the joint, initially for creation of the engaging HS defect, but also for access for performing the remplissage and Latarjet procedures. The LTO has been shown to preserve shoulder stability and range of motion (14). Testing was conducted on the intact shoulder, following creation and repair of the lesser tuberosity osteotomy, and again after creation of a soft-tissue Bankart lesion. Additionally, specimens were tested after creation of a 25% HS defect and following treatment with the remplissage and Latarjet procedures.

The HS defect was created in accordance with the work of Sekiya et al. and Yamamoto et al. (17,18). The specimens were positioned in 90° of combined abduction (30° of scapular abduction and 60° of glenohumeral abduction) and 60° of external

rotation. The anteroinferior glenoid margin was then observed and a mark parallel to this was placed on the humeral head to simulate the orientation of the HS defect. The width of the head was then measured perpendicular to this line using a digital caliper and a 25% defect was created in this orientation at the posterosuperior aspect of the humeral head with a microsagittal saw.

The remplissage procedure was performed by placing two single-loaded suture anchors (Super Revo, ConMed Linvatec, Largo, Florida) into the valley of the HS defect. The accompanying sutures were then passed through the posterior capsule and infraspinatus tendon using a straight-needle. Horizontal mattress sutures were then tied, inseting these soft tissue structures into the HS defect.

The Latarjet procedure was performed in the classic manner using 2 screws for fixation as described earlier (19). The coracoid body was exposed and osteotomized at its angle while leaving the conjoint tendon attachment intact. A horizontal split in the subscapularis was then made at the junction of the middle and inferior thirds. The coracoid and attached conjoint tendon were passed through this split. The coracoid was then fixed to the anteroinferior glenoid rim using two 3.75 mm cannulated cortical screws (Arthrex, Naples, FL) of sufficient length to achieve bicortical fixation.

3.2.4 Experimental Protocol & Outcome Variables

Rotational range of motion was assessed by internally and externally rotating the arm in both abduction and adduction. The boundaries of this were determined when a pre-defined resisting torque of 0.8 Nm was achieved, consistent with the resistance felt during routine clinical assessment as defined by a pilot study.

Glenohumeral joint stability was assessed with the manual application of an 80-N quasistatic force to the posterior aspect of the humeral head in the anteroinferior direction. This load was applied through a uni-axial load-cell (Model 34 Precision Miniature, Honeywell, Golden Valley, Minnesota). Tracking allowed for calculation of joint stiffness (N/mm) based on the amount of anterior humeral head translation measured with the applied force. The force was continued until a dislocation occurred or

a soft-tissue endpoint was reached. Both engagement and shoulder dislocation were determined by two observers and corroborated with the optical tracking data that showed an abrupt medialization of the humeral head relative to the glenoid. Joint stiffness was assessed with the humerus adducted and abducted, in both neutral and 60° of external rotation. Horizontal extension ROM was also assessed with the arm in a position of 90° of combined abduction and 60° of external rotation.

3.2.5 Data and Statistical Analysis

Glenohumeral motion, joint stiffness, and the incidence of glenohumeral dislocation were monitored for the above-mentioned testing parameters. One-way Analysis of Variance (ANOVA) tests and pairwise comparisons were conducted for each outcome variable utilizing a statistical software package (SPSS Inc., Chicago, IL). Significance was set at $p < 0.05$.

3.3 Results

3.3.1 Joint Stiffness

In adduction, with the arm in neutral rotation, the remplissage procedure had significantly greater joint stiffness (12.7 ± 3.7 N/mm) compared to the Latarjet (7.0 ± 2.3 N/mm, $p=0.003$), with neither procedure being significantly different than intact (8.7 ± 3.3 N/mm, $p=1.0$) (Figure 3-1). In adduction, external rotation, no significant differences were noted in joint stiffness ($p=0.137$) (Figure 3-2).

In abduction with the arm in neutral rotation, no significant differences ($p=0.907$) in joint stiffness were noted between the remplissage (5.5 ± 3.2 N/mm) and the Latarjet procedures (5.7 ± 3.3 N/mm) (Figure 3-3). In abduction, external rotation, the 'position of apprehension', the defect state was significantly less stiff (more unstable) than the intact state ($p=0.029$). Both the remplissage and the Latarjet procedures were able to

restore joint stiffness values to near intact levels, with no significant differences in stiffness between them ($p>0.08$) (Figure 3-4).

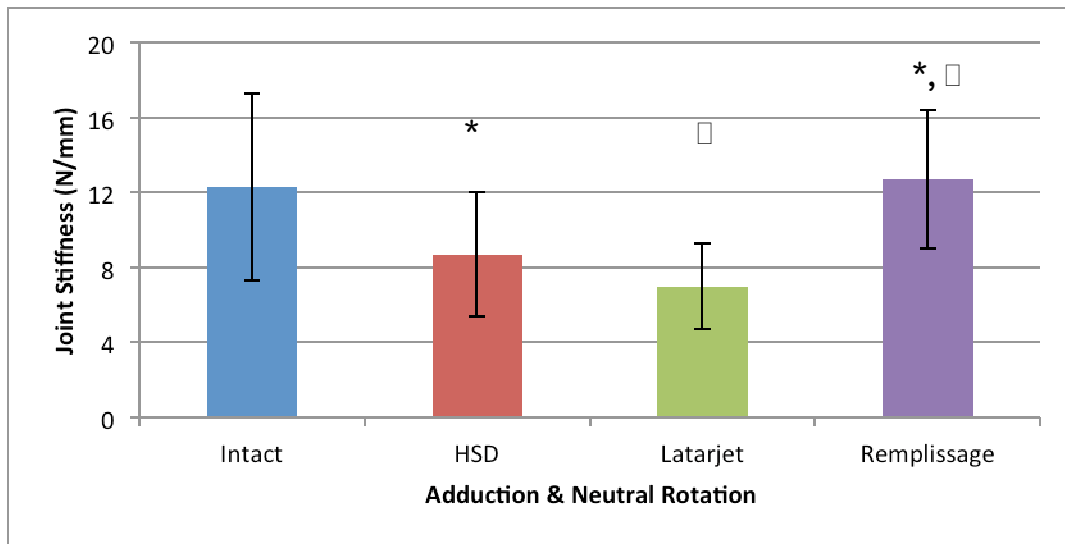


Figure 3-1. Joint Stiffness in Adduction and Neutral Rotation

Joint stiffness \pm 1 SD (N/mm) in adduction and neutral rotation revealed that the remplissage procedure increased stiffness relative to the Hill-Sachs defect state and the Latarjet reconstruction group, however there were no significant differences in any group compared with the intact joint stiffness. (Statistical significance in pair-wise comparisons denoted by corresponding symbols)

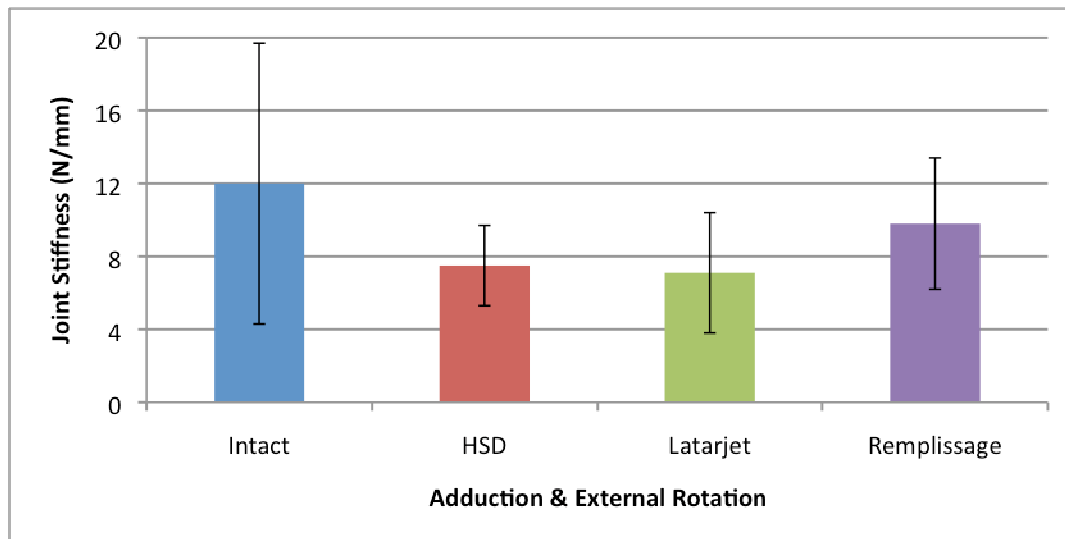


Figure 3-2. Joint Stiffness in Adduction and External Rotation

Joint stiffness \pm 1 SD (N/mm) in adduction and external rotation did not find any significant differences between testing groups.

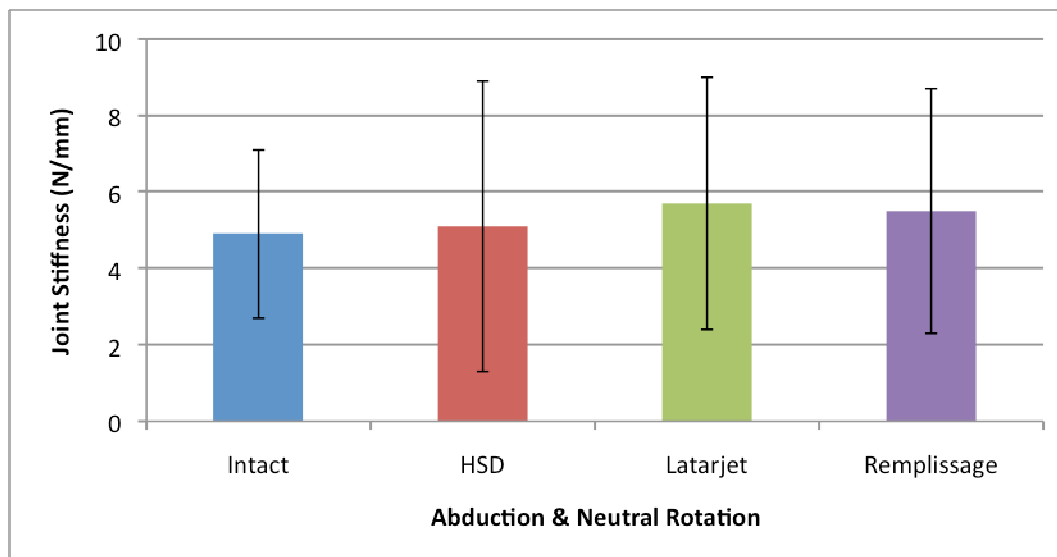


Figure 3-3. Joint Stiffness in Abduction and Neutral Rotation

Joint stiffness \pm 1 SD (N/mm) in abduction and neutral rotation did not find any significant differences between testing groups.

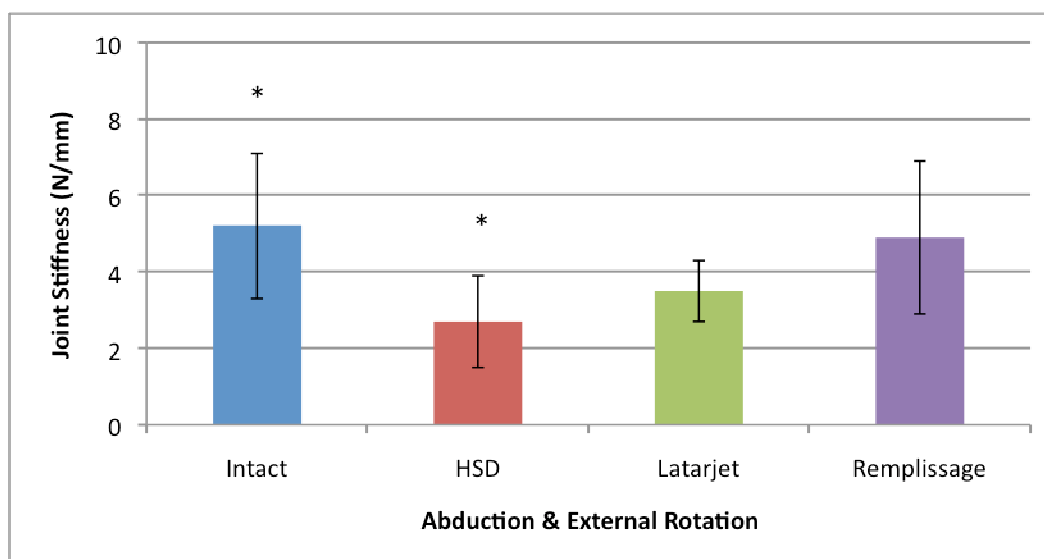


Figure 3-4. Joint Stiffness in Abduction and External Rotation

Joint stiffness \pm 1 SD (N/mm) in abduction and external rotation found only that the Hill-Sachs defect group was more unstable than the intact condition, and that both reconstruction techniques adequately restored joint stiffness. (Statistical significance in pair-wise comparisons denoted by corresponding symbols)

3.3.2 Range of Motion

With the arm in an adducted position, no significant effect on internal/external range of motion (IR/ER ROM) was noted ($p>0.24$) (Figure 3-5). With the humerus abducted, the Latarjet procedure significantly reduced the overall IR/ER ROM ($48.9\pm 13.7^\circ$) relative to the HS defect state ($69.1\pm 17.4^\circ$; $p=0.009$), while the remplissage procedure did not limit this motion ($68.6\pm 12.0^\circ$; $p=1.0$). Neither procedure significantly altered the ROM compared to the intact specimen ($62.2\pm 18.3^\circ$, $p>0.13$) (Figure 3-6).

Testing in the position of apprehension with the arm in abduction and external rotation, the remplissage procedure significantly reduced horizontal extension range of motion ($16.1\pm 12.1^\circ$) relative to the Latarjet procedure ($34.4 \pm 7.8^\circ$, $p=0.043$), while the Latarjet procedure did not affect this motion relative to the HS defect state ($34.3 \pm 7.6^\circ$, $p=1.0$). Once again, neither procedure significantly affected extension ROM compared to the intact specimen ($29.7\pm 10.5^\circ$, $p>0.19$) (Figure 3-7).

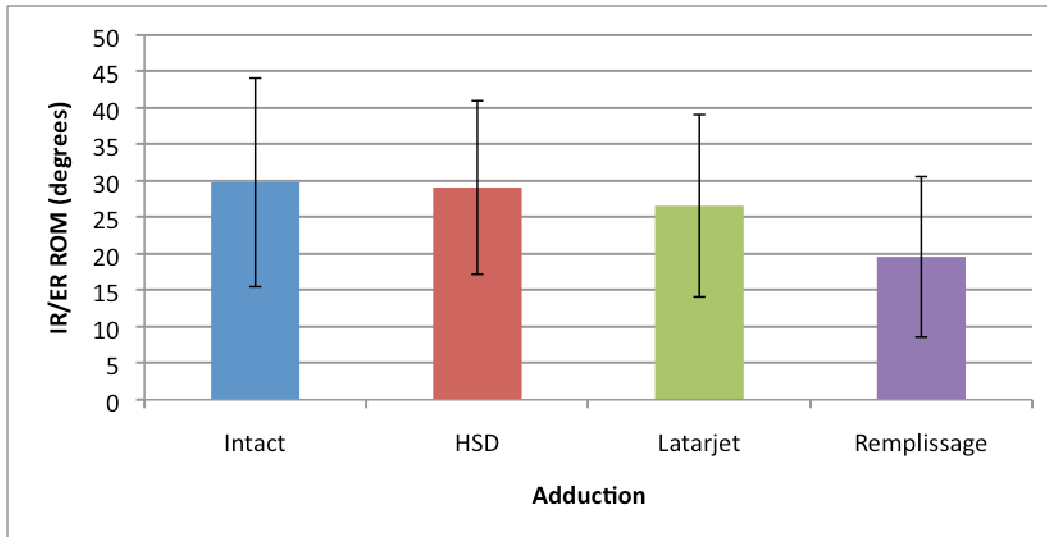


Figure 3-5. Internal/External Range of Motion in Adduction

Internal and external range of motion \pm 1 SD reported for all testing configurations in adduction revealed no significant differences between groups.

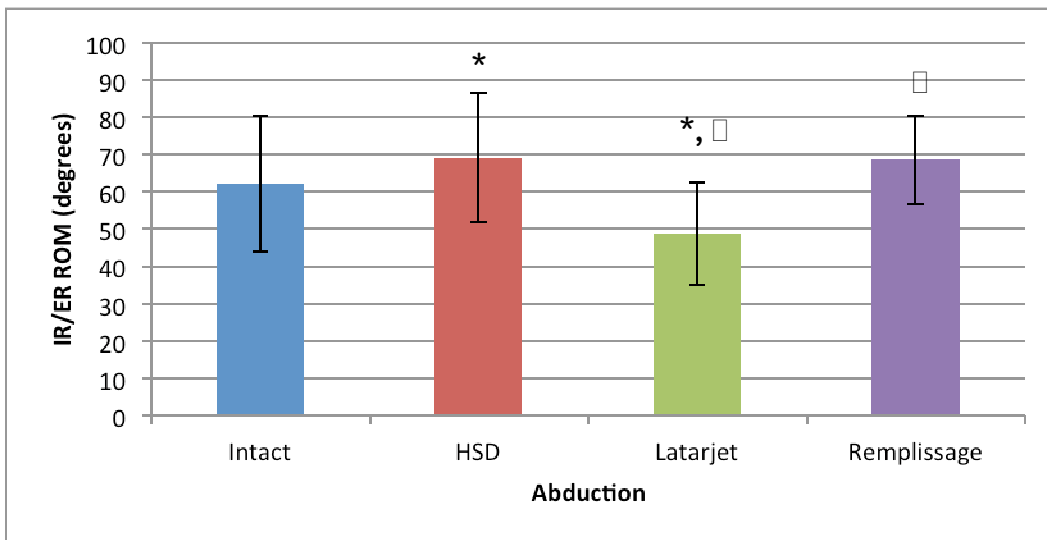


Figure 3-6. Internal/External Range of Motion in Abduction

Internal and external range of motion \pm 1 SD reported for all testing configurations in abduction revealed no significant differences between the defect or reconstruction groups when compared with the intact condition. The Latarjet procedure limited this range of motion relative to the remplissage procedure and Hill-Sachs defect group. (Statistical significance in pair-wise comparisons denoted by corresponding symbols)

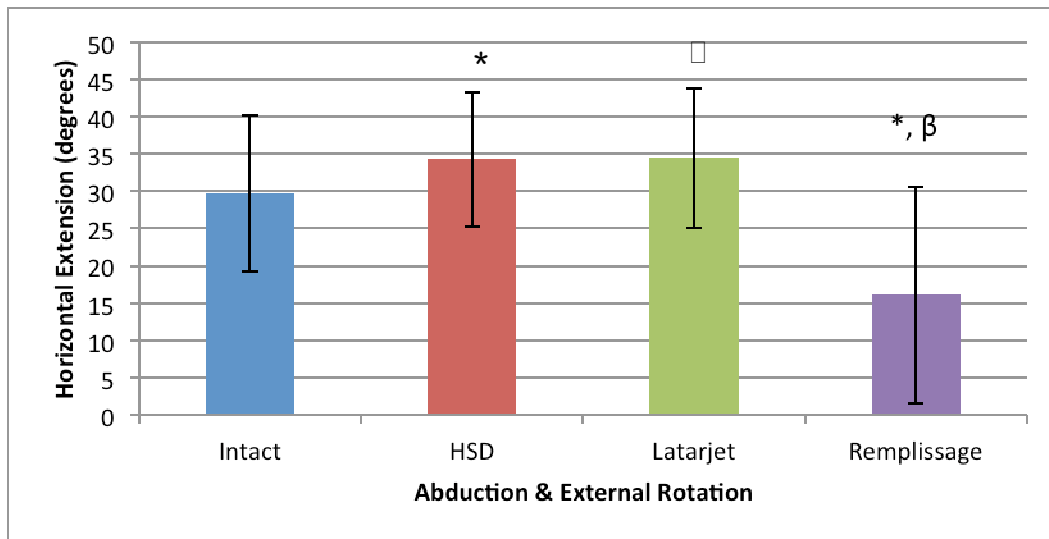


Figure 3-7. Horizontal Extension Range of Motion in Abduction and External Rotation (60°)

Horizontal extension range of motion ± 1 SD revealed no significant limitations following either reconstruction procedure relative to the intact state. The remplissage group did limit this motion relative to the Latarjet reconstruction group and Hill-Sachs defect groups. (Statistical significance in pair-wise comparisons denoted by corresponding symbols)

3.3.3 Incidence of Dislocation

None of the intact specimens dislocated. After creation of the Hill-Sachs defect, seven of eight specimens dislocated in both abduction-neutral rotation and abduction-external rotation (Table 3-1). With the arm in adduction, the remplissage and Latarjet procedures effectively stabilized all specimens, with no dislocations occurring. Testing in abduction following the remplissage procedure, two and three dislocations occurred with the arm in neutral and external rotation, respectively. Following the Latarjet procedure, only one specimen dislocated in either position.

	HS Defect	Latarjet	Remplissage
Abduction & Neutral Rotation	7	1	2
Abduction & External Rotation	7	1	2

Table 3-1. Incidence of Dislocation following Anteroinferiorly Directed 80N Force.

Number of dislocations (out of a possible 8 specimens per group) that occurred following application of an anteroinferior force measured at 80N. Both the Latarjet and remplissage procedures reduced the number of dislocations nearly equally.

3.4 Discussion

The treatment of engaging Hill-Sachs defects remains controversial. While studies have shown the role these defects play in perpetuating instability (2,5), a consensus on the best treatment option remains to be determined (3). Generally, defects <20% of the humeral head width, in association with capsulolabral tears, are adequately stabilized with an isolated soft-tissue Bankart repair (3,20). Defects of 20-40% also require operative stabilization, although decision making in this setting is particularly challenging, as there is a lack of comparative literature on the existing treatment options (3,6,9). The various procedures can be separated into two classes – anatomic and non-anatomic, where anatomic procedures attempt to recreate the normal proximal humeral head convexity and sphericity, and non-anatomic procedures attempt to limit engagement of the Hill-Sachs defect (3,6,9,17,21). Of the non-anatomic procedures, proponents of the remplissage favor this procedure because it can be done arthroscopically, heals in a predictable fashion with minimal limitations on ROM, and is associated with success rates of up to 98% (9,22). On the other hand, proponents of the Latarjet coracoid transfer favor this because of the conferred “triple effect” on stability, which includes restoring the glenoid arc, providing a “sling effect” via the transferred conjoint tendon and subscapularis tensioning, and repairing the joint capsule with augmentation via the coracoacromial ligament, all of which confer a success rate of up to 95% (4). No comparative studies exist to support one over the other. As a result, we attempted to provide biomechanical data on these two non-anatomic procedures to support their use in the setting of recurrent instability with a HS defect. Additionally, we monitored their effect on range of motion (IR/ER and horizontal extension) and joint stability (joint stiffness and incidence of dislocation).

Neither procedure significantly affected the IR/ER range of motion with the humerus adducted. Following remplissage, reductions in this arc of motion were seen, although they did not reach statistical significance ($p=0.08$). This trend, however, was similar to the results seen in a study by Elkinson et al. (2012), where IR/ER motion was found to be significantly reduced with the humerus adducted following remplissage (20).

Similar to their results, testing in abduction produced no significant effect, likely due to a decrease in rotator cuff tension in the abducted position (20). Conversely, following the Latarjet procedure there was no significant effect in adduction on IR/ER range of motion, while in abduction a 29.2% decrease in IR/ER range of motion relative to the HS defect state was noted ($p=0.009$). This is likely attributable to the tensioning effect on the inferior capsule and lower subscapularis fibers provided by the conjoint tendon with increasing external rotation (8).

Horizontal extension was reduced by 53% following the remplissage procedure ($p=0.038$) relative to the Hill-Sachs defect state. This could be due to the fact that the inset posterior capsule and infraspinatus tendon form a “bumper” that impinges on the posterior glenoid rim, limiting extension, but also preventing defect engagement (20). This was detected as gapping of the glenohumeral joint in our tracking data, which confirmed the endpoint of extension caused by this soft-tissue impingement. The Latarjet coracoid transfer, however, did not significantly affect horizontal extension in this position of testing ($p=1.0$).

Joint stiffness in adduction was significantly increased following the remplissage procedure with the arm in neutral rotation ($p=0.016$), while the Latarjet procedure did not produce the same effect. In adduction, external rotation, no significant effects were noted on joint stiffness following either procedure. This difference between neutral and external rotation following remplissage is likely attributable to the decrease in tension of the inset soft tissues during external rotation testing, which lessens the resistive force to anterior translation. Additionally, the Latarjet likely produced minimal effect in adduction because of the low-lying position of the conjoint tendon, which would not produce its “sling effect” until tensioned in abduction and external rotation.

Stiffness in abduction was not significantly affected in neutral rotation following either procedure. Presumably, with the arm abducted, the posterosuperior portion of the rotator cuff and capsule again experience the same decrease in tension mentioned earlier, explaining the lack of effect noted here as well. The Latarjet’s sling effect likely would not have come into play without significant anterior translation. In the abducted,

externally rotated position, the remplissage procedure increased stiffness relative to the HS defect state, while the Latarjet procedure did not. We felt this was likely due to the fact that externally rotating the arm in the abducted position tensioned the posterior, superior portion of the inset rotator cuff and capsule, resulting in a greater resistance to anterior translation, although statistical significance was not reached ($p=0.08$). The lack of effect in the Latarjet group is again explained by the significant distance that the humeral head would have had to travel to engage the sling effect, which did not occur.

Finally, for our secondary outcome measure, we noted that neither group experienced a dislocation in the adducted position. Following remplissage, two and three dislocations were noted in the abducted, neutrally rotated and abducted, externally rotated positions respectively, while only one dislocation was seen in both of those conditions following the Latarjet coracoid transfer. Aside from the observed trends, no further conclusions can be drawn from this data as we were not powered to detect a statistically significant difference in the incidence of joint dislocation.

From our results we are able to reject our initial hypothesis, as it appears that both the remplissage and Latarjet coracoid transfer equally restored joint stiffness, while neither significantly limited range of motion of the shoulder in comparison to the intact cohort.

Limitations of this study are those inherent in cadaveric studies, including the use of elderly specimens and that our results represent time-zero biomechanics. Additionally, the remplissage procedure is typically performed arthroscopically, but given our testing set-up this was not possible. Performing this with the joint opened via our lesser tuberosity osteotomy could have potentially affected where our sutures were passed into the capsule and rotator cuff, as the tissues were not draped over the HS defect as they would be in an arthroscopic scenario. This likely created a worst-case scenario with respect to the adequacy of tension of our inset soft-tissues, but still provided adequate stability.

3.5 Conclusions

This study investigated the biomechanical effects of the remplissage and Latarjet procedures in the treatment of a moderately-sized engaging Hill-Sachs defect (25%), simulating a scenario of recurrent glenohumeral instability. Both the remplissage and Latarjet procedures improved joint stability, reducing the overall incidence of dislocation, while having minimal effect on global shoulder ROM. Further clinical studies are required to determine the functional significance of the slight restrictions in ROM following the remplissage procedure for IR/ER motion in abduction, and following the Latarjet procedure for horizontal extension in the abducted, externally rotated position. Presently, our data supports both procedures as efficacious treatments of this clinical scenario.

3.6 References

1. Balg F, Boileau P. The instability severity index score. A simple pre-operative score to select patients for arthroscopic or open shoulder stabilisation. *The Journal of bone and joint surgery. British volume.* 2007 Nov;89(11):1470–7.
2. Burkhart SS, De Beer JF. Traumatic glenohumeral bone defects and their relationship to failure of arthroscopic Bankart repairs: significance of the inverted-pear glenoid and the humeral engaging Hill-Sachs lesion. *Arthroscopy®: the journal of arthroscopic & related surgery®: official publication of the Arthroscopy Association of North America and the International Arthroscopy Association.* 2000 Oct;16(7):677–94.
3. Provencher MT, Frank RM, Leclere LE, Metzger PD, Ryu JJ, Bernhardson A, et al. The Hill-Sachs lesion: diagnosis, classification, and management. *The Journal of the American Academy of Orthopaedic Surgeons.* 2012 Apr;20(4):242–52.
4. Burkhart SS, De Beer JF, Barth JRH, Cresswell T, Criswell T, Roberts C, et al. Results of modified Latarjet reconstruction in patients with anteroinferior instability and significant bone loss. *Arthroscopy®: the journal of arthroscopic & related surgery®: official publication of the Arthroscopy Association of North America and the International Arthroscopy Association.* 2007 Oct;23(10):1033–41.
5. Boileau P, Villalba M, Héry JY, Balg F, Ahrens P, Neyton L. Risk factors for recurrence of shoulder instability after arthroscopic Bankart repair. *The Journal of bone and joint surgery. American volume.* 2006 Aug;88(8):1755–63.
6. Armitage MS, Faber KJ, Drosdowech DS, Litchfield RB, Athwal GS. Humeral head bone defects: remplissage, allograft, and arthroplasty. *The Orthopedic clinics of North America.* 2010 Jul;41(3):417–25.
7. Purchase RJ, Wolf EM, Hobgood ER, Pollock ME, Smalley CC. Hill-sachs “remplissage”: an arthroscopic solution for the engaging hill-sachs lesion. *Arthroscopy®: the journal of arthroscopic & related surgery®: official publication*

- of the Arthroscopy Association of North America and the International Arthroscopy Association. 2008 Jun;24(6):723–6.
8. Giles JW, Boons HW, Elkinson I, Faber KJ, Ferreira LM, Johnson JA, et al. Does the dynamic sling effect of the Latarjet procedure improve shoulder stability? A biomechanical evaluation. *Journal of shoulder and elbow surgery / American Shoulder and Elbow Surgeons ... [et al.]*. 2013 Jun 27;22(6):821–7.
 9. Skendzel JG, Sekiya JK. Diagnosis and management of humeral head bone loss in shoulder instability. *The American journal of sports medicine*. 2012 Nov;40(11):2633–44.
 10. Wellmann M, Petersen W, Zantop T, Herbort M, Kobbe P, Raschke MJ, et al. Open shoulder repair of osseous glenoid defects: biomechanical effectiveness of the Latarjet procedure versus a contoured structural bone graft. *The American journal of sports medicine*. 2009 Jan;37(1):87–94.
 11. Veeger HE, Van der Helm FC, Van der Woude LH, Pronk GM, Rozendal RH. Inertia and muscle contraction parameters for musculoskeletal modelling of the shoulder mechanism. *Journal of biomechanics*. 1991 Jan;24(7):615–29.
 12. Kedgley AE, Mackenzie GA, Ferreira LM, Drosdowech DS, King GJW, Faber KJ, et al. The effect of muscle loading on the kinematics of in vitro glenohumeral abduction. *Journal of biomechanics*. 2007 Jan;40(13):2953–60.
 13. Kedgley AE, Mackenzie GA, Ferreira LM, Johnson JA, Faber KJ. In vitro kinematics of the shoulder following rotator cuff injury. *Clinical biomechanics (Bristol, Avon)*. 2007 Dec;22(10):1068–73.
 14. Giles JW, Elkinson I, Ferreira LM, Faber KJ, Boons H, Litchfield R, et al. Moderate to large engaging Hill-Sachs defects: an in vitro biomechanical comparison of the remplissage procedure, allograft humeral head reconstruction, and partial resurfacing arthroplasty. *Journal of shoulder and elbow surgery / American Shoulder and Elbow Surgeons ... [et al.]*. 2012 Sep;21(9):1142–51.
 15. Giles JW, Boons HW, Ferreira LM, Johnson JA, Athwal GS. The effect of the conjoined tendon of the short head of the biceps and coracobrachialis on shoulder stability and kinematics during in-vitro simulation. *Journal of biomechanics*. 2011 Apr 7;44(6):1192–5.

16. Poppen NK, Walker PS. Forces at the glenohumeral joint in abduction. *Clinical orthopaedics and related research*. 1978 Sep;(135):165–70.
17. Sekiya JK, Wickwire AC, Stehle JH, Debski RE. Hill-Sachs defects and repair using osteoarticular allograft transplantation: biomechanical analysis using a joint compression model. *The American journal of sports medicine*. 2009 Dec;37(12):2459–66.
18. Yamamoto N, Itoi E, Abe H, Minagawa H, Seki N, Shimada Y, et al. Contact between the glenoid and the humeral head in abduction, external rotation, and horizontal extension: a new concept of glenoid track. *Journal of shoulder and elbow surgery / American Shoulder and Elbow Surgeons ... [et al.]*. 16(5):649–56.
19. Latarjet M. [Treatment of recurrent dislocation of the shoulder]. *Lyon chirurgical*. 1954;49(8):994–7.
20. Elkinson I, Giles JW, Faber KJ, Boons HW, Ferreira LM, Johnson JA, et al. The effect of the remplissage procedure on shoulder stability and range of motion: an in vitro biomechanical assessment. *The Journal of bone and joint surgery. American volume*. 2012 Jun 6;94(11):1003–12.
21. Yagishita K, Thomas BJ. Use of allograft for large Hill-Sachs lesion associated with anterior glenohumeral dislocation. A case report. *Injury*. 2002 Nov;33(9):791–4.
22. Boileau P, O'Shea K, Vargas P, Pinedo M, Old J, Zumstein M. Anatomical and functional results after arthroscopic Hill-Sachs remplissage. *The Journal of bone and joint surgery. American volume*. 2012 Apr 4;94(7):618–26.

Chapter 4

4 A Biomechanical Assessment of Superior Shoulder Translation after Reconstruction for Anterior Glenoid Bone Loss: The Latarjet Procedure versus Allograft Reconstruction

Overview

In the previous chapters, the biomechanical effects of the Latarjet coracoid transfer have been reviewed in the treatment of recurrent instability with glenoid deficiency, as well as an engaging Hill-Sachs lesion. This chapter serves to explore the negative biomechanical effects of this procedure, particularly focusing on the degree of conferred superior instability that may result from resection of the coracoacromial ligament.

(A version of this chapter has been accepted for publication in the International Journal of Shoulder Surgery. Written permission has been granted by the publisher to reprint this version and can be found in the appendix.)

4.1 Introduction

The role of the coracoacromial arch, specifically that of the coracoacromial ligament, in superior shoulder stability has been well established (1–5). The majority of early reports focused primarily on the role of the coracoacromial ligament in the rotator cuff deficient shoulder (1,5–7). The inferior concave surface of the coracoacromial ligament acts as a static restraint, along with the acromion, to resist superior translation of the humeral head. Conceptually, with coracoacromial ligament resection in the setting of a large rotator cuff tear or prior surgery, the humeral head may be predisposed to anterosuperior migration, or “escape” (7,8). In light of this, more attention has been

focused on the coracoacromial ligament to define its role in glenohumeral joint stability and kinematics.

In vitro biomechanical studies have been performed to illustrate the role of the coracoacromial ligament in superior stability. These studies have demonstrated, but not quantified, increased superior translation following coracoacromial ligament resection with varying forces applied to the shoulder (2–4,7,8). As a result, it was advocated to maintain the integrity of this structure whenever possible to avoid destabilizing the glenohumeral joint. While most studies focused on superior instability, there is also a relationship between coracoacromial ligament resection and anterior glenohumeral instability. An intact coracoacromial ligament is thought to interact with the coracohumeral ligament to provide restraint to anterior and inferior translation, as coracoacromial ligament resection has been shown to result in increased anteroinferior instability, indicating that its role in shoulder stability is larger than historically presumed (3,4).

The Latarjet procedure, which involves a transfer of the coracoid along with the conjoined tendon, is an attractive surgical option for the management of anterior shoulder instability in the setting of bony defects (9,10). The Latarjet, as classically described (9), involves transfer of the coracoid body with its inferior surface fixed to the anterior glenoid vault. Recently, the congruent-arc modification of the Latarjet has been described which rotates the graft 90° so its inferior surface is oriented flush with the glenoid articular surface (11). The congruent-arc Latarjet has been reported to have a better radius of curvature match to the native glenoid (12), better normalization of glenohumeral contact pressures (13) and reconstitutes a greater glenoid bone defect than

a coracoid oriented in the classic manner, theoretically improving anteroinferior stability (12,13).

The literature reports that the Latarjet coracoid transfer has been largely successful, with recurrence rates as low as 4.9% after 5 years and good to excellent patient outcomes (14,15). With the excellent success rates reported, little attention has been paid to the potential negative kinematic effects that may be associated with resection of important soft-tissue stabilizers. Both variations of the Latarjet transfer involve division of the coracoacromial ligament, which has been reported as an important structure in shoulder stability, particularly in those with rotator cuff disease. Biomechanical studies investigating the Latarjet procedure have mimicked our excitement over the stabilizing effects and have primarily focused on anteroinferior stability (16), while the resultant effects on superior shoulder translation, with resection of this important stabilizing structure, remain unknown. Presently, no clinical data exists demonstrating the degree of superior instability conferred by the Latarjet procedure. The purpose of this *in vitro* biomechanical study was to examine the effect of both versions of the Latarjet coracoid transfer and associated coracoacromial ligament resection on superior shoulder translation in an axially loaded shoulder in different static positions. This may have particular relevance to the unique population with concomitant shoulder instability and rotator cuff disease. We hypothesized that a structural coracoid allograft reconstruction, utilizing a coracoid process obtained from a donor cadaver allowing preservation of the test specimen's coracoacromial ligament, would retain superior stability, while the Latarjet oriented in the classic manner and the congruent-arc

modification would both lead to increased superior translation, irrespective of the loading condition.

4.2 Materials and Methods

4.2.1 Specimen Preparation

Eight, right-sided, fresh-frozen cadaveric forequarter specimens were used (average age 73 years, range 69-91 years). Prior to dissection, specimen CT scans were obtained and reviewed to ensure those with pathology, such as osteoarthritis or trauma, were excluded. Specimens were prepared by transecting the humerus mid-shaft and removing attached soft tissues, while preserving the deltoid and its insertion, the rotator cuff muscles, both heads of the biceps, as well as the glenohumeral joint capsule. Image guidance was used to assist in cementing a steel-intramedullary rod fitted with a six degree-of-freedom (DOF) load cell (Mini45, ATI Industrial Automation, Apex, NC) (Figure 4.1) into the proximal shaft of the humerus. Prior to resection of the humerus, a temporary optical marker was rigidly fixed to the proximal humerus and the locations of the epicondyles were digitized. After humeral resection, the rod, which was also instrumented with an optical marker, was cemented in place while aligning it with the virtual transepicondylar axis recorded with respect to the temporary humeral marker. The distal end of the rod was then attached to the simulator via a spherical bearing that allowed four degrees of freedom, which in turn permitted full glenohumeral translation and rotation. Once attached to the simulator by the scapula pot and the spherical bearing, it was possible to manipulate the shoulder into repeatable glenohumeral orientations through adjustment of the custom stability testing apparatus (Figure 4-1).




Figure 4-1. Mounted Shoulder Specimen

Figure of a cadaveric specimen mounted on the custom-designed shoulder simulator. Soft tissues removed for clarity. The apparatus is capable of independently controlling scapular elevation, and glenohumeral abduction, flexion, and humeral internal-external rotation. (A) Six (6) degrees of freedom optical tracking markers, (B) Interposed six degrees of freedom humeral load cell, (C) Miniature actuators used to load long head of biceps and conjoint tendon, (D) Scapula mounting pot, (E) Spherical bearing used to connect humeral rod to apparatus without restricting glenohumeral kinematics.

4.2.2 Shoulder Simulator

(The shoulder simulator employed in this study is similar to the system described in Chapters 2 and 3. The description to follow, while partially redundant, is included to be consistent with the publication version of this chapter.)

The *in vitro* shoulder simulator allowed unconstrained glenohumeral motion (Figure 4-1). Simulated loads were applied to eight shoulder muscle groups (three heads of the deltoid, supraspinatus, infraspinatus and teres minor, subscapularis, long head of biceps and the conjoined group) after passing sutures (#5 Ethibond, Ethicon, Somerville, NJ) through their musculotendinous junctions. Conjoint tendon and long head of biceps loading were achieved by suturing the tendons and passing the sutures through eyelets placed on the humerus that replicated the muscles' natural lines of action. Sutures were connected to two miniature pneumatic actuators mounted on the humerus. The conjoint tendon was loaded with 10 N based on a previous study assessing conjoint tendon loading (17). The supraspinatus, subscapularis, and the combination of the infraspinatus and teres minor were all loaded with 7.5 N each. The anterior, lateral and posterior heads of the deltoid were each loaded with 5N (18–21).

Optical markers (Optotrak Certus, NDI, Waterloo, ON) were mounted on the scapula and humerus, and digitizations were made in order to create an Euler rotation sequence consistent with ISB standards (22). Specifically, digitizations of the inferior angle, root of the spine, and the posterolateral aspect of the acromion were made on the scapula and used to create a scapular coordinate system. On the humerus, the previous medial and lateral epicondylar digitizations were used in addition to the center of the

humeral head, which was determined from kinematic recordings, to construct a humeral coordinate system (23–25).

4.2.3 Testing Protocol

The protocol was designed to test the effect of coracoacromial ligament resection, following classic and congruent-arc Latarjet procedures, on superior shoulder translation in an axially loaded specimen with and without simulated muscle loads. Repetitive access to the glenohumeral joint was required in keeping with the repeated measures design of the study. In order to allow this without compromising stability with subsequent tests, access was gained via an extended lesser tuberosity osteotomy. The osteotomy was then fixed using two bicortical 1/8” nut-and-bolt constructs to ensure rigid fixation after each exposure. Previous studies have found that shoulder stability and range of motion have not been significantly affected with this technique (20). Once the joint was accessed, points were digitized on the glenoid and were used to create a coordinate system for assessing humeral head translations.

Five conditions were tested for each specimen in this protocol: intact specimen, 30% anterior glenoid bone defect, allograft coracoid reconstruction, classic Latarjet procedure, and the congruent-arc modification of the Latarjet. After the intact specimen was tested, a 30% anterior glenoid bone defect was created following the protocol detailed by Yamamoto et al (2009) (26). Reference was made to the work of Saito et al. (2005) who demonstrated that a typical defect associated with anterior shoulder instability can be found in the “3:01 o’clock” position on the glenoid (27). Calipers were used to identify a 30% glenoid segment starting from the anterior rim, which was then resected with a microsagittal saw.

After testing the 30% anterior glenoid bony defect, an allograft coracoid was affixed to the anterior aspect of the glenoid in the region of the previously created defect (Figure 4-2a). The allograft coracoid specimens, obtained from additional cadaveric specimens, were size- and side-matched to ensure appropriate fit. The preparation and orientation of the graft was similar to that described for the classic Latarjet procedure (9,28). The graft was secured to the glenoid with two 3.5 mm cortical screws.

After testing the allograft coracoid specimen, classic or congruent-arc Latarjet procedures were performed in a randomized fashion (9,28). The coracoid body was exposed and osteotomized at its angle. The attached conjoint tendon was transferred with the coracoid to the anterior glenoid, passed through a subscapularis split and loaded via an actuator on the humeral shaft. For the classic technique, the inferior surface of the coracoid was fixed to the glenoid with two 3.5mm cortical screws (Figure 4-2b). The congruent-arc technique was performed as described by De Beer et al (11) with rotation of the graft 90° so that the inferior surface would sit flush with the glenoid articular surface (Figure 4-2c). For each state, specimens were tested with and without a load applied to the rotator cuff, conjoint tendon, long head of biceps and anterior, lateral and posterior heads of the deltoid.

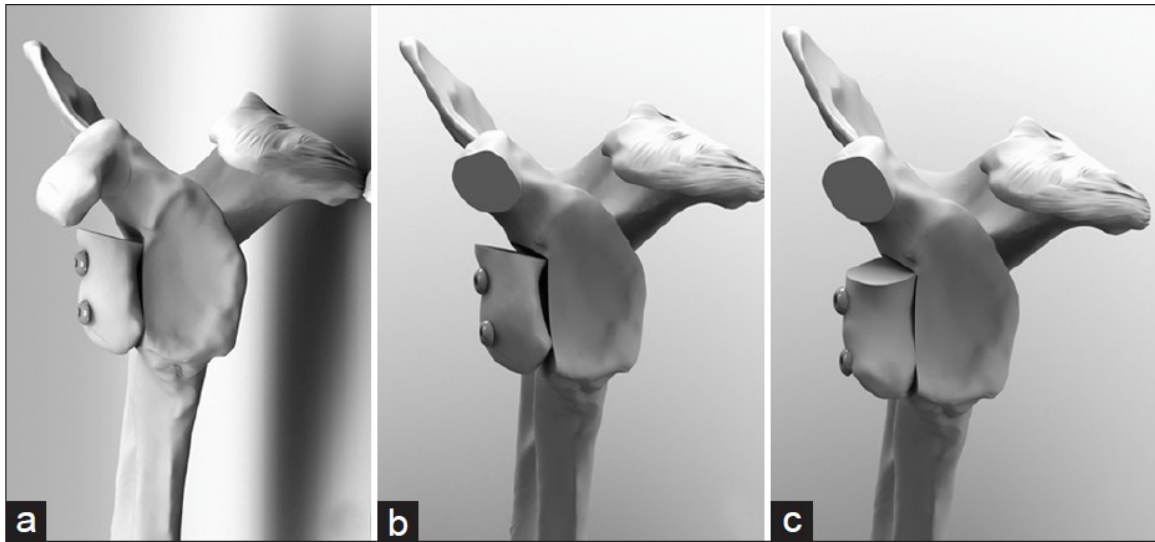


Figure 4-2. Coracoid Reconstructions of a 30% Glenoid Defect

Figures of the various coracoid reconstructions used for a 30% glenoid defect. Allograft coracoid reconstruction with coracoid secured in keeping with Classic Latarjet description (a), Classic Latarjet coracoid transfer (b), and Congruent-Arc Latarjet coracoid transfer (c) are demonstrated. Note that in each rendering, all soft tissues are omitted for clarity. Also, in the case of the allograft reconstruction the coracoacromial ligament is preserved.

4.2.4 Stability Testing

Superior joint stability was tested in three configurations: (1) neutral rotation (2) internal rotation and (3) external rotation all in 0° of flexion, and 0° of abduction. The positions of internal and external rotation were established by rotating the humerus until a pre-defined torque of ± 0.8 Nm was achieved. This magnitude was set based on repeated clinical examinations of a pilot specimen by an orthopedic surgeon until meeting resistance consistent with routine clinical examination, measuring on average 0.8 Nm.

Superior glenohumeral joint stability was measured by determining superior humeral head translation while applying a quasi-static axial load up to 80 N. The magnitude of humeral head translation was defined as the maximum point of displacement along the y-axis, measured in millimeters, following a maximum applied force of 80 N. Two loading cycles were applied to the specimens in each particular condition and position. The six degrees-of-freedom humeral load cell was used for real-time feedback and to record the applied load, while joint kinematics were quantified using the optical tracking markers.

4.2.5 Statistical Analysis

Statistical analyses were conducted with a statistical package (SPSS Inc., Chicago, IL), using a combination of one-way repeated measures Analyses of Variance (ANOVAs) and pairwise comparisons. Each analysis consisted of five levels: intact, 30% glenoid bone defect, allograft coracoid, and the classic and congruent arc Latarjet procedures. Significance was set at $p < 0.05$.

4.3 Results

4.3.1 Humeral Head Translation: Neutral Rotation

In the neutral position without muscle loading, a statistically significant increase in superior translation was noted with the classic Latarjet procedure as compared to the 30% anterior glenoid bone defect ($3.4 \text{ mm} \pm 2.3$, $p=0.046$) and the allograft coracoid reconstruction ($3.1 \text{ mm} \pm 2.1$, $p=0.041$). The congruent-arc Latarjet did not result in significantly greater superior translation ($p>0.05$) and the allograft coracoid reconstruction was not significantly different than the intact condition ($p=1.0$) (Figure 4-3).

After activation and loading of the shoulder girdle muscles, the overall magnitude of translation decreased in all conditions; however, superior translation after the classic Latarjet was significantly greater than the intact state ($1.2 \text{ mm} \pm 0.6$, $p=0.005$) and the allograft coracoid reconstruction ($0.9 \text{ mm} \pm 0.4$, $p=0.002$). Similarly, during active muscle loading the congruent arc Latarjet was also found to have significantly greater superior translation compared to both the intact condition ($1.5 \text{ mm} \pm 0.9$, $p=0.018$) and the allograft reconstruction ($1.2 \text{ mm} \pm 0.7$, $p=0.021$). The allograft coracoid reconstruction, however, was not significantly different than the intact condition ($p=1.0$). Additionally, no significant differences ($p=1.0$) were found between the classic and the congruent-arc Latarjet conditions with respect to superior translation in neutral rotation, with or without muscle loading. (Figure 4-3)

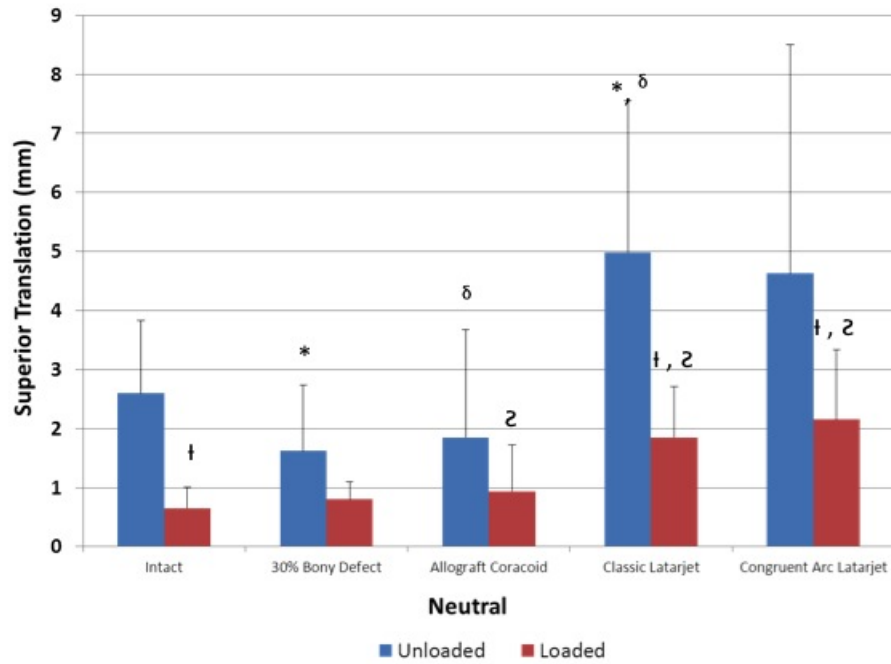


Figure 4-3. Superior Translation in Adduction and Neutral Rotation.

Superior humeral head translation \pm 1 SD (in mm) in adduction and neutral rotation reported for both loaded and unloaded states with different joint conditions. Pair-wise comparisons with statistical significance are denoted with corresponding symbols.

4.3.2 Humeral Head Translation: Internal Rotation

In glenohumeral internal rotation without muscle loading, there were no significant increases in humeral head superior translation between the conditions ($p>0.05$). With physiologic loads applied to the muscle groups, the overall magnitudes of translation decreased. However, a significant increase in superior translation occurred after the classic Latarjet as compared to the intact ($1.7 \text{ mm} \pm 1.1$, $p=0.041$), 30% bone defect ($1.5 \text{ mm} \pm 0.9$, $p=0.022$) and the allograft coracoid reconstruction ($1.3 \text{ mm} \pm 0.9$, $p=0.037$). In contrast, the congruent arc Latarjet was not found to be significantly different from any other condition ($p>0.078$). No significant differences were noted between the allograft coracoid reconstruction and the intact condition ($p=1.0$). Additionally, no significant differences ($p=1.0$) were found between the classic and the congruent-arc Latarjet procedures with respect to superior translation in internal rotation, with or without muscle loading (Figure 4-4).

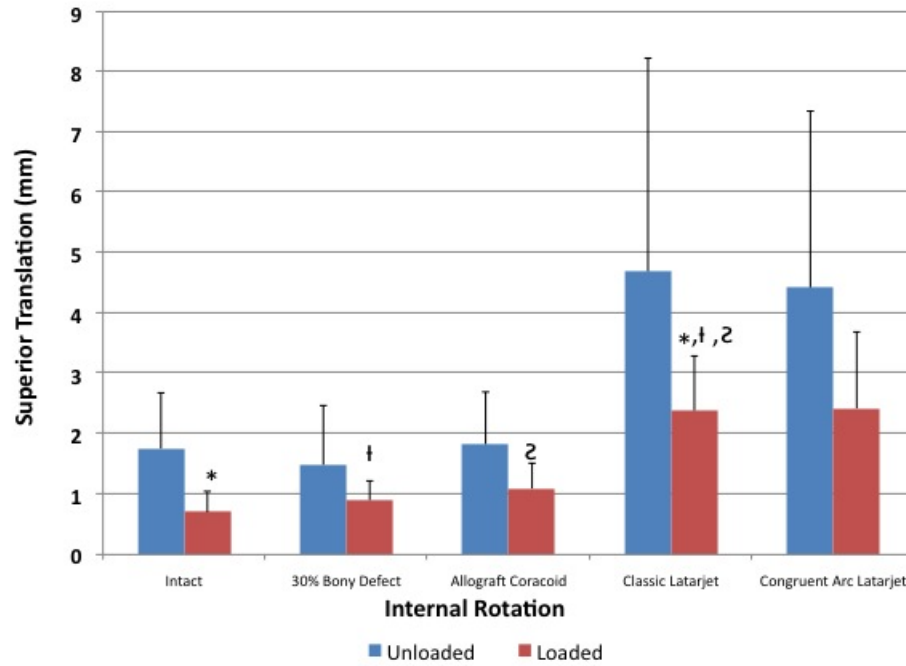


Figure 4-4. Superior Translation in Adduction and Internal Rotation.

Superior humeral head translation ± 1 SD (in mm) in adduction and internal rotation reported for both loaded and unloaded states with different joint conditions. Pair-wise comparisons with statistical significance are denoted with corresponding symbols.

4.3.3 Humeral Head Translation: External Rotation

In external rotation without muscle loading, the classic and the congruent-arc Latarjet procedures were found to have significantly greater superior humeral head translation as compared to the intact condition ($3.2 \text{ mm} \pm 2.0$, $p=0.028$ and $2.6 \text{ mm} \pm 1.5$, $p=0.017$, respectively), while the allograft coracoid reconstruction was not significantly different from intact ($1.1 \text{ mm} \pm 1.7$, $p=0.991$) (Figure 4-5).

With the application of physiologic muscle loading, no significant differences were identified between the conditions ($p>0.05$). Additionally, no significant differences ($p=1.0$) were found between the classic and the congruent-arc Latarjet procedures with respect to superior translation in external rotation, with or without muscle loading.

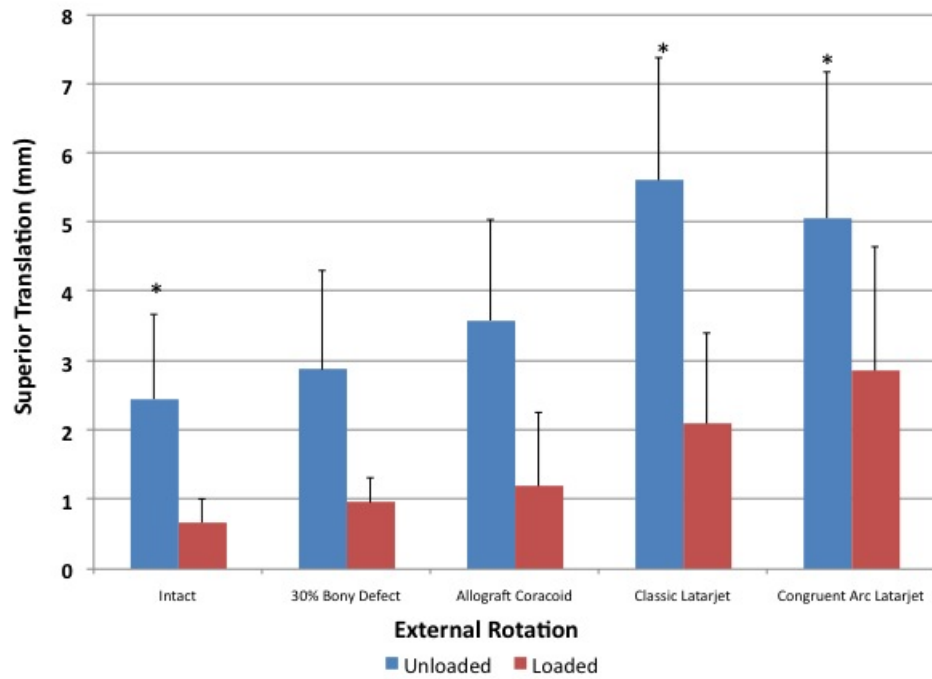


Figure 4-5. Superior Translation in Adduction and External Rotation.

Superior humeral head translation ± 1 SD (in mm) in adduction and external rotation reported for both loaded and unloaded states with different joint conditions. Pair-wise comparisons with statistical significance are denoted with corresponding symbols.

4.3.4 Humeral Head Translation: Load Effect

In all positions, across all conditions, applying physiologic muscle loading to the rotator cuff, the long head of biceps, the conjoined tendon, and the deltoid muscle reduced the overall magnitude of superior displacement. In the unloaded neutral position, testing produced the largest magnitude of superior translation with a maximum mean of 5.0 mm (± 2.6 mm), which occurred after the classic Latarjet. Applying a simulated load reduced this value to 1.8 mm (± 0.9 mm) of displacement.

In internal rotation, maximum translation with the unloaded muscle groups was seen in the classic Latarjet condition as well, with an average superior translation of 4.7 mm (± 3.5 mm). Applying a load in this position reduced the average translation to a maximum of 2.4 mm (± 0.9 mm).

In external rotation in the unloaded state, the maximum average superior translation was measured at 5.6 mm (± 1.8 mm) once again in the classic Latarjet condition, while loading the cuff reduced maximum translation to 2.1 mm (± 1.3 mm).

4.4 Discussion

The effect of coracoacromial ligament resection on superior shoulder translation has been demonstrated in several biomechanical studies; however, these have largely focused on the effect in rotator cuff-deficient shoulders or those with symptoms of impingement (1–3,5,7). To date, no study has investigated the effect of coracoacromial ligament resection in patients with anteroinferior instability undergoing a stabilizing Latarjet coracoid transfer procedure. Our results indicate that performing a Latarjet

procedure can lead to an increase risk of superior shoulder translation in most joint configurations and loading conditions. This highlights the importance of the coracoacromial ligament as a restraint to superior humeral head translation, even in cases with an intact rotator cuff. Additionally, we compared the Latarjet procedures with allograft coracoid reconstruction and found that the allograft procedure did not significantly differ from the intact condition for the parameters examined. The clinical significance of these findings is not definitely known. We believe that these results improve our understanding of the biomechanics of the Latarjet procedure, exposing a potentially negative kinematic effect that may have relevance in particular patient populations, such as older patients with concomitant rotator cuff disease. This may help identify patient sub-groups that may be better served with alternative reconstructive procedures.

In our model, the application of physiologic muscle loads dampened the abnormal superior displacement values after the Latarjet procedures. This reduction in the overall magnitude of superior translation was evident across all states and in all tested positions. This likely relates to the static stabilizing features of a concentrically reduced loaded glenohumeral joint, and the dynamic stabilizing effect of the tensioned rotator cuff muscles (29–31). This knowledge of the important stabilizing effects of the rotator cuff muscles reaffirms the importance of post-operative muscle strengthening protocols, which may be especially important after a Latarjet procedure.

Glenohumeral joint positioning had substantial effects on the magnitude of superior humeral head translation. While only slight differences in superior translation were present in the neutral position, marked significant differences were noted in the

internal and external rotation positions between the different loading cycles. In the internally rotated position, no significant differences were found in the unloaded group between the various states; however, physiologic muscle loading resulted in significant increases in superior translation in the classic Latarjet group as compared to all states with an intact coracoacromial ligament. Muscle loading and terminal rotation may allow the physiologic restraints of the specific ligamentous stabilizers to function at their correct length and tension (32), and resection of key stabilizing structures in this condition will exemplify their role in superior stability.

In external rotation, the unloaded states demonstrated significantly increased superior translation in the classic and congruent-arc Latarjet groups as compared to intact ($p=0.028, 0.017$). Applying physiologic muscle loads, however, resulted in no significant differences in superior translation for either state. This may relate to the natural posterosuperior translation that occurs in the loaded, externally rotated shoulder, perhaps negating the importance of the coracoacromial ligament as significant translations may be reduced by the tensioned anterior glenohumeral ligaments (29,30).

In addition to testing the effects of the Latarjet procedures on superior translation, we also tested a structural allograft coracoid reconstruction condition with an intact coracoacromial ligament. For the allograft, we chose an allograft coracoid, obtained from a donor cadaver, oriented in the classic Latarjet manner that was contoured to sit flush with the glenoid articular surface. Testing of the allograft demonstrated that there were no significant differences in superior translations between it and the intact condition in any scenario tested ($p>0.05$). The obvious benefit of the allograft procedure is that it allows preservation of the native coracoacromial arch, presumably decreasing any

superior translation that would arise due to coracoacromial ligament disruption. The use of allograft, however, is not without potential risks, such as graft resorption, disease transmission, and cost.

Clinical studies have reported that the average acromiohumeral distance measures between 10-15 mm in healthy individuals and 7 mm in patients with large rotator cuff tears (33). The greatest magnitudes of superior translation in the present study occurred with the classic Latarjet procedure without loading with a mean of 5.6 mm, while with loading the maximum mean dropped to 2.1 mm. With physiologic muscle loading, the overall mean superior translation with the Latarjet procedures was 2.3 mm. Although the values for superior translation following the Latarjet were usually found to be statistically significant, it is unknown whether they are clinically significant. Further studies are needed to determine the manifestations of superior shoulder translation following Latarjet coracoid transfer to determine if the allograft coracoid procedure has a potentially beneficial role by maintaining superior stability (33). Although the allograft coracoid reconstruction may maintain superior stability, it lacks the sling effect of the conjoint tendon transfer of the Latarjet, which is theorized to provide additional dynamic stability to the glenohumeral joint (16). Careful patient selection for the utilization of one particular surgical procedure over another is required. For example, older patients with recurrent instability, glenoid bone loss and rotator cuff disease, may be found to do better with structural glenoid bone grafting over a Latarjet procedure.

The congruent-arc modification of the Latarjet, which rotates the coracoid graft 90° relative to the classic Latarjet procedure, has several purported advantages including a matching radius of curvature to the glenoid and the ability to reconstitute greater

glenoid bone loss. Due to the matching radius of curvature and the potential for greater bony conformity and constraint, it is conceivable that the coracoid oriented in the congruent manner could decrease superior humeral head translation. Our results, however, indicate that there were no significant differences ($p>0.05$) between the congruent-arc modification and the classic Latarjet with regard to superior translation.

Limitations of this study are consistent with those of other cadaveric studies, including the use of elder donor specimens. Additionally, the findings reported represent time-zero effects for specific joint configurations and load conditions, and thus it is not possible to extrapolate long-term outcomes or effects of other joint conditions.

4.5 Conclusion

The classic and congruent-arc Latarjet procedures, which disrupt the coracoacromial ligament, increase superior humeral head translation. Superior translation after glenoid reconstruction with a structural coracoid allograft, however, is not substantially different from the intact condition. Further clinical studies are required to elucidate the implications of increased superior translation due to the Latarjet reconstruction.

4.6 References

1. Torrens C, López JM, Verdier E, Marín M. Open anterior acromioplasty with preservation of the coracoacromial ligament: A modified surgical technique. *Journal of shoulder and elbow surgery / American Shoulder and Elbow Surgeons ... [et al.]*. 2003;12(1):9–14.
2. Wellmann M, Petersen W, Zantop T, Schanz S, Raschke MJ, Hurschler C. Effect of coracoacromial ligament resection on glenohumeral stability under active muscle loading in an in vitro model. *Arthroscopy*: the journal of arthroscopic & related surgery: official publication of the Arthroscopy Association of North America and the International Arthroscopy Association. 2008 Nov;24(11):1258–64.
3. Su W-R, Budoff JE, Luo Z-P. The effect of coracoacromial ligament excision and acromioplasty on superior and anterosuperior glenohumeral stability. *Arthroscopy*: the journal of arthroscopic & related surgery: official publication of the Arthroscopy Association of North America and the International Arthroscopy Association. 2009 Jan;25(1):13–8.
4. Lee TQ, Black AD, Tibone JE, McMahan PJ. Release of the coracoacromial ligament can lead to glenohumeral laxity: a biomechanical study. *Journal of shoulder and elbow surgery / American Shoulder and Elbow Surgeons ... [et al.]*. 2001;10(1):68–72.
5. Wiley AM. Superior humeral dislocation. A complication following decompression and debridement for rotator cuff tears. *Clinical orthopaedics and related research*. 1991 Feb;(263):135–41.
6. Fagelman M, Sartori M, Freedman KB, Patwardhan AG, Carandang G, Marra G. Biomechanics of coracoacromial arch modification. *Journal of shoulder and elbow surgery / American Shoulder and Elbow Surgeons ... [et al.]*. 2007;16(1):101–6.

7. Hockman DE, Lucas GL, Roth CA. Role of the coracoacromial ligament as restraint after shoulder hemiarthroplasty. *Clinical orthopaedics and related research*. 2004 Feb;(419):80–2.
8. Denard PJ, Bahney TJ, Kirby SB, Orfaly RM. Contact pressure and glenohumeral translation following subacromial decompression: how much is enough? *Orthopedics*. 2010 Nov;33(11):805.
9. Latarjet M. [Treatment of recurrent dislocation of the shoulder]. *Lyon chirurgical*. 1954;49(8):994–7.
10. Young AA, Maia R, Berhouet J, Walch G. Open Latarjet procedure for management of bone loss in anterior instability of the glenohumeral joint. *Journal of shoulder and elbow surgery / American Shoulder and Elbow Surgeons ... [et al.]*. 2011 Mar;20(2 Suppl):S61–9.
11. De Beer JF, Roberts C. Glenoid bone defects--open latarjet with congruent arc modification. *The Orthopedic clinics of North America*. 2010 Jul;41(3):407–15.
12. Armitage MS, Elkinson I, Giles JW, Athwal GS. An anatomic, computed tomographic assessment of the coracoid process with special reference to the congruent-arc latarjet procedure. *Arthroscopy*: the journal of arthroscopic & related surgery: official publication of the Arthroscopy Association of North America and the International Arthroscopy Association. 2011 Nov;27(11):1485–9.
13. Ghodadra N, Gupta A, Romeo AA, Bach BR, Verma N, Shewman E, et al. Normalization of glenohumeral articular contact pressures after Latarjet or iliac crest bone-grafting. *The Journal of bone and joint surgery. American volume*. 2010 Jun;92(6):1478–89.
14. Hovelius L, Vikersfors O, Olofsson A, Svensson O, Rahme H. Bristow-Latarjet and Bankart: a comparative study of shoulder stabilization in 185 shoulders during a seventeen-year follow-up. *Journal of shoulder and elbow surgery / American Shoulder and Elbow Surgeons ... [et al.]*. 2011 Oct;20(7):1095–101.
15. Burkhart SS, De Beer JF, Barth JRH, Cresswell T, Criswell T, Roberts C, et al. Results of modified Latarjet reconstruction in patients with anteroinferior instability and significant bone loss. *Arthroscopy*: the journal of arthroscopic & related surgery: official publication of the Arthroscopy Association of North

- America and the International Arthroscopy Association. 2007 Oct;23(10):1033–41.
16. Wellmann M, De Ferrari H, Smith T, Petersen W, Siebert CH, Agneskirchner JD, et al. Biomechanical investigation of the stabilization principle of the Latarjet procedure. *Archives of orthopaedic and trauma surgery*. 2012 Mar;132(3):377–86.
 17. Giles JW, Boons HW, Ferreira LM, Johnson JA, Athwal GS. The effect of the conjoined tendon of the short head of the biceps and coracobrachialis on shoulder stability and kinematics during in-vitro simulation. *Journal of biomechanics*. 2011 Apr 7;44(6):1192–5.
 18. Wellmann M, Petersen W, Zantop T, Herbort M, Kobbe P, Raschke MJ, et al. Open shoulder repair of osseous glenoid defects: biomechanical effectiveness of the Latarjet procedure versus a contoured structural bone graft. *The American journal of sports medicine*. 2009 Jan;37(1):87–94.
 19. Veeger HE, Van der Helm FC, Van der Woude LH, Pronk GM, Rozendal RH. Inertia and muscle contraction parameters for musculoskeletal modelling of the shoulder mechanism. *Journal of biomechanics*. 1991 Jan;24(7):615–29.
 20. Giles JW, Elkinson I, Ferreira LM, Faber KJ, Boons H, Litchfield R, et al. Moderate to large engaging Hill-Sachs defects: an in vitro biomechanical comparison of the remplissage procedure, allograft humeral head reconstruction, and partial resurfacing arthroplasty. *Journal of shoulder and elbow surgery / American Shoulder and Elbow Surgeons ... [et al.]*. 2012 Sep;21(9):1142–51.
 21. Poppen NK, Walker PS. Forces at the glenohumeral joint in abduction. *Clinical orthopaedics and related research*. 1978 Sep;(135):165–70.
 22. Wu G, Van der Helm FCT, Veeger HEJD, Makhsous M, Van Roy P, Anglin C, et al. ISB recommendation on definitions of joint coordinate systems of various joints for the reporting of human joint motion--Part II: shoulder, elbow, wrist and hand. *Journal of biomechanics*. 2005 May;38(5):981–92.
 23. Woltring HJ. Estimation of the trajectory of the instantaneous centre of rotation in planar biokinematics. *Journal of biomechanics*. 1990 Jan;23(12):1273–4.

24. Ehrig RM, Taylor WR, Duda GN, Heller MO. A survey of formal methods for determining the centre of rotation of ball joints. *Journal of biomechanics*. 2006 Jan;39(15):2798–809.
25. Monnet T, Desailly E, Begon M, Vallée C, Lacouture P. Comparison of the SCoRE and HA methods for locating in vivo the glenohumeral joint centre. *Journal of biomechanics*. 2007 Jan;40(15):3487–92.
26. Yamamoto N, Itoi E, Abe H, Kikuchi K, Seki N, Minagawa H, et al. Effect of an anterior glenoid defect on anterior shoulder stability: a cadaveric study. *The American journal of sports medicine*. 2009 May;37(5):949–54.
27. Saito H, Itoi E, Sugaya H, Minagawa H, Yamamoto N, Tuoheti Y. Location of the glenoid defect in shoulders with recurrent anterior dislocation. *The American journal of sports medicine*. 2005 Jun;33(6):889–93.
28. Helfet AJ. Coracoid transplantation for recurring dislocation of the shoulder. *The Journal of bone and joint surgery. British volume*. 1958;40(B):198–202.
29. Bigliani LU, Kelkar R, Flatow EL, Pollock RG, Mow VC. Glenohumeral stability. Biomechanical properties of passive and active stabilizers. *Clinical orthopaedics and related research*. 1996 Sep;(330):13–30.
30. Novotny JE, Beynnon BD, Nichols CE. Modeling the stability of the human glenohumeral joint during external rotation. *Journal of biomechanics*. 2000 Mar;33(3):345–54.
31. Lugo R, Kung P, Ma CB. Shoulder biomechanics. *European journal of radiology*. 2008 Oct;68(1):16–24.
32. Itoi E, Berglund LJ, Grabowski JJ, Naggar L, Morrey BF, An KN. Superior-inferior stability of the shoulder: role of the coracohumeral ligament and the rotator interval capsule. *Mayo Clinic proceedings. Mayo Clinic*. 1998 Jun;73(6):508–15.
33. Seitz AL, Michener LA. Ultrasonographic measures of subacromial space in patients with rotator cuff disease: A systematic review. *Journal of clinical ultrasound* □: JCU. 2011;39(3):146–54.

Chapter 5

5 General Discussion & Conclusions

Complex shoulder instability continues to pose a challenging clinical problem. While retrospective and cadaveric studies have identified the role that bony defects play in recurrent instability (1,2), the optimal methods of treatment had not been well established. The goals of this thesis were to examine the stabilizing effect of the Latarjet coracoid transfer in the management of both a glenoid deficient shoulder and with an engaging Hill-Sachs defect, while additionally comparing it with the stabilizing effects of alternate procedures to attempt to identify the biomechanically superior procedure.

Several objectives were established to determine the biomechanical effects the Latarjet and alternate stabilization procedures. These objectives were completed and conclusions established from our work. These will be briefly summarized and put into further context on their impact in the treatment of complex shoulder instability. To review, the objectives were:

1. To compare the stabilizing effect of the Bristow and Latarjet coracoid transfers in the setting of various different glenoid defects
2. To compare the stabilizing effect of the remplissage and Latarjet coracoid transfer in the setting of an engaging 25% Hill-Sachs defect, and
3. To determine the degree of superior shoulder instability following Latarjet coracoid transfer

Correspondingly, the hypotheses were:

1. The Latarjet coracoid transfer will provide improved shoulder stability in comparison to the Bristow coracoid transfer for all glenoid defect states.

2. The Latarjet coracoid transfer will provide improved shoulder stability, and less restricted range of motion compared to the remplissage procedure in the treatment of an engaging Hill-Sachs defect.
3. The Latarjet coracoid transfer will result in greater superior shoulder migration compared to bone augmentation procedures that do not violate the coracoacromial ligament.

5.1 Bristow versus Latarjet Coracoid Transfer (Chapter 2)

This study set out to compare the stabilizing effects of the classically described Bristow coracoid transfer, involving transfer of only the coracoid tip (3), and Latarjet coracoid transfer, involving transfer of the entire horizontal pillar of the coracoid (4), in the setting of worsening glenoid deficiency (0, 15 & 30% defects). The hypothesis that the Latarjet coracoid transfer would outperform the Bristow in all settings was not completely supported, as the Bristow coracoid transfer was able to restore stiffness, or the resistance to anterior humeral translation, back to levels consistent with baseline parameters following the capsulolabral injury in the abducted position. However, once the 15% and 30% glenoid defects were introduced, the Latarjet offered improved stability, preventing nearly all dislocations, while the Bristow was inadequate in restoring joint stability.

Both reconstruction procedures limited axial rotation across all three defect states in the abducted position when compared with the intact group. Comparing between the two techniques, for the abducted position with an isolated capsulolabral lesion with an intact glenoid, the Latarjet coracoid transfer significantly limited axial rotation relative to the Bristow procedure, potentially giving the Bristow procedure one advantageous clinical scenario over the Latarjet where it can stabilize the joint effectively while providing an improved amount of axial rotation.

Alternatively, one could argue that based on the results of this study, the Bristow may have no clinical utility, as it only proved sufficient in stabilizing the joint with a

capsulolabral injury and was insufficient even with a small 15% defect. Previous cadaveric studies have shown that a soft-tissue Bankart repair or stabilization is sufficient at stabilizing the joint until a defect of >21% is present (5,6). The argument could be made that at defect levels of <20% a coracoid transfer is not indicated, and beyond that, the Latarjet outperformed the Bristow and should be the procedure of choice.

Finally, these results alert the reader that further literature reporting on the long-term outcomes of the “Bristow-Latarjet” coracoid transfer should be carefully scrutinized, with particular attention focused on the description of the surgical procedure(7). Higher failure rates may be associated with the Bristow, but reported for both, giving the Latarjet procedure a poorer perceived outcome when in actuality it may represent a viable surgical option when performed as originally described.

5.2 Remplissage versus Latarjet Coracoid Transfer (Chapter 3)

This study compared the stabilizing effect of the remplissage capsulotenodesis (8)with the Latarjet coracoid transfer in the treatment of an engaging 25% Hill-Sachs defect. The hypothesis that the Latarjet would provide improved stability, without the reported deleterious effect associated with the remplissage of restricted range of motion, was disproven. Both procedures adequately stabilized the joint, with no significant limitations on range of motion when compared with the intact specimen. The remplissage group did have slightly increased residual instability with a larger number of dislocations post-intervention.

Consistent with reports from other studies (9–11), the remplissage procedure limited the internal-external range of motion arc in the adducted position compared to the Latarjet, although the effect also did not reach statistical significance. In the abducted position this effect was no longer observed and, interestingly, the Latarjet was found to significantly decrease this arc of motion relative to the remplissage. This was thought to be due to tensioning of the lower subscapularis fibers caused by the conjoined tendon. Neither procedure significantly altered the range of motion relative to the intact group.

The data on joint stiffness following these procedures is useful and allows physicians to note that both procedures are effective for management of a Hill-Sachs lesion of this size, as both sufficiently restored stiffness to near intact levels. The goal of non-anatomic stabilization procedures is to limit external rotation to prevent Hill-Sachs defect engagement, which these options successfully achieved. However, the functional ramifications of the slightly decreased range of motion following both procedures remain to be determined. Patients may find the reduced range of motion interferes with their activities of daily living, or alternatively, may not notice any limitations and may feel subjectively better as they are unable to reach the extreme positions of motion that would have often been proprioceptively associated with a sensation of apprehension. Further clinical research should focus on patient satisfaction following both procedures, as well as on their measured range of motion to see if restrictions exist, and if so, whether they are long lasting or decrease with time as a result of soft-tissue attenuation or creep.

5.3 Superior Shoulder Instability following Latarjet Coracoid Transfer (Chapter 4)

After studying the beneficial effects of the Latarjet coracoid transfer for treatment of both a glenoid defect and engaging Hill-Sachs defect in recurrent instability, the objective of this final study was to monitor for negative biomechanical effects conferred by the procedure. Specifically, attention was focused on the degree of superior shoulder instability following performance of the Latarjet coracoid transfer, which involves sectioning of the coracoacromial ligament (CAL), a known restraint to superior translation of the shoulder, particularly in the setting of rotator cuff disease. The hypothesis that the Latarjet coracoid transfer would result in greater superior migration relative to bone augmentation procedures that did not require CAL resection was supported in this study.

This study was the first to our knowledge to test superior instability with an intact rotator cuff. Both versions of the Latarjet procedure, the classically described and the congruent-arc modification, produced similar results with increased superior translation when compared to bone augmentation procedures. These results draw attention to the fact that this procedure is not without risk, and while it may represent an attractive option

for those suffering from recurrent instability with one of the aforementioned sized lesions, the potential negative effects should not be ignored.

Additional studies have compared the Latarjet coracoid transfer with bone block reconstruction of the glenoid, finding the stabilization effect of the Latarjet to be greater, so the application of our results is presently limited. While increased superior translation certainly exists following the Latarjet, it may still be the preferred procedure given that it does a better job of restoring shoulder stability. Unfortunately, as of now, we are only aware of this significant increase in superior translation, while the clinical impact of this translation remains unknown. The purpose of this study was to identify and demonstrate the magnitude of this finding, although the focus of future work should be on the clinical effect that may be associated with this increase in superior translation.

5.4 Cadaveric Testing

While the limitations of cadaveric testing were briefly outlined in each chapter's respective discussion, including the fact that our results represent time-zero biomechanics and that our average specimen age was greater than 70 years of age, cadaveric testing also offers several distinct advantages compared to alternative biomechanical studies. The predominant benefit is the replication of the true structural, morphological and mechanical properties of the *in vivo* specimens (12). A major advantage is the ability to apply muscular loading across the joint, which was utilized in our testing protocol. Preserving muscular attachments and subsequently applying loads across the joint, allows for reproduction of a more physiologic environment, taking advantage of the joint's normal static and dynamic stabilizers, providing more clinically applicable results (12).

Cadaveric testing, while potentially limited in its ability to produce directly clinically applicable results, is a necessity in orthopedic research. It allows for assessment of new implants or treatment techniques, studying their fatigue failure and fixation failure. Positive results in biomechanical analyses utilizing cadaveric specimens are a near-requisite before moving into the clinical realm of treatment and possible study with clinical trials. The aim of this type of research should be to provide results that

generate hypotheses for clinical trials, allowing for further study to corroborate these *in vitro* results with *in vivo* results, which has been achieved with our studies.

5.5 Conclusion

Results from this work will contribute to the management of complex shoulder instability. The efficacy of both the Bristow and Latarjet coracoid transfers for recurrent instability with an isolated capsulolabral injury was demonstrated, while subsequently showing the superiority of the Latarjet to the Bristow for moderate to large glenoid defects (15-30% glenoid width). Additionally, both the Latarjet and Remplissage procedures were identified as adequate stabilization procedures for managing recurrent instability with an engaging Hill-Sachs defect, with minimal restrictions on ROM. Finally, potential complications associated with the Latarjet procedure were noted with an increase in superior shoulder translation following completion of this procedure for recurrent instability, albeit the clinical implications of this are not yet known.

Presently, these results represent *in vitro* kinematics, and further study should focus on their *in vivo* clinical effects.

5.6 References

1. Boileau P, Villalba M, Héry JY, Balg F, Ahrens P, Neyton L. Risk factors for recurrence of shoulder instability after arthroscopic Bankart repair. *The Journal of bone and joint surgery. American volume*. 2006 Aug;88(8):1755–63.
2. Burkhart SS, De Beer JF. Traumatic glenohumeral bone defects and their relationship to failure of arthroscopic Bankart repairs: significance of the inverted-pea glenoid and the humeral engaging Hill-Sachs lesion. *Arthroscopy*: the journal of arthroscopic & related surgery: official publication of the Arthroscopy Association of North America and the International Arthroscopy Association. 2000 Oct;16(7):677–94.

3. Helfet AJ. Coracoid transplantation for recurring dislocation of the shoulder. *The Journal of bone and joint surgery. British volume.* 1958;40(B):198–202.
4. Latarjet M. [Treatment of recurrent dislocation of the shoulder]. *Lyon chirurgical.* 1954;49(8):994–7.
5. Yamamoto N, Itoi E, Abe H, Kikuchi K, Seki N, Minagawa H, et al. Effect of an anterior glenoid defect on anterior shoulder stability: a cadaveric study. *The American journal of sports medicine.* 2009 May;37(5):949–54.
6. Piasecki DP, Verma NN, Romeo AA, Levine WN, Bach BR, Provencher MT. Glenoid bone deficiency in recurrent anterior shoulder instability: diagnosis and management. *The Journal of the American Academy of Orthopaedic Surgeons.* 2009 Aug;17(8):482–93.
7. Hovelius L, Sandström B, Sundgren K, Saebö M. One hundred eighteen Bristow-Latarjet repairs for recurrent anterior dislocation of the shoulder prospectively followed for fifteen years: study I--clinical results. *Journal of shoulder and elbow surgery / American Shoulder and Elbow Surgeons ... [et al.].* 13(5):509–16.
8. Purchase RJ, Wolf EM, Hobgood ER, Pollock ME, Smalley CC. Hill-sachs “remplissage”: an arthroscopic solution for the engaging hill-sachs lesion. *Arthroscopy* □: the journal of arthroscopic & related surgery □: official publication of the Arthroscopy Association of North America and the International Arthroscopy Association. 2008 Jun;24(6):723–6.
9. Elkinson I, Giles JW, Faber KJ, Boons HW, Ferreira LM, Johnson JA, et al. The effect of the remplissage procedure on shoulder stability and range of motion: an in vitro biomechanical assessment. *The Journal of bone and joint surgery. American volume.* 2012 Jun 6;94(11):1003–12.
10. Elkinson I, Giles JW, Boons HW, Faber KJ, Ferreira LM, Johnson JA, et al. The shoulder remplissage procedure for Hill-Sachs defects: does technique matter? *Journal of shoulder and elbow surgery / American Shoulder and Elbow Surgeons ... [et al.].* 2013 Jun 26;22(6):835–41.
11. Boileau P, O’Shea K, Vargas P, Pinedo M, Old J, Zumstein M. Anatomical and functional results after arthroscopic Hill-Sachs remplissage. *The Journal of bone and joint surgery. American volume.* 2012 Apr 4;94(7):618–26.

12. Gardner MJ, Silva MJ, Krieg JC. Biomechanical testing of fracture fixation constructs: variability, validity, and clinical applicability. *The Journal of the American Academy of Orthopaedic Surgeons*. 2012 Feb;20(2):86–93.

Appendix A: Glossary

Abduction	Physiologic motion that involves moving the part in question away from the midline of the body or adjacent part of the limb
Adduction	Physiologic motion that involves moving the part in question toward the midline of the body or adjacent part of the limb
Allograft	Tissue from a donor of the same species
Autograft	A tissue graft from the same individual used in a different location
Anteversion	Anatomical reference of something being tipped forward
Articular surface	Joint surface
Articulation	A joint or juncture between bones or cartilages in the skeleton of a vertebrate
Avulsion fracture	When a fragment of bone is torn away from the main segment by attached soft tissues
Axial rotation	Rotatory movement of an object around its own axis; specifically in the shoulder, it refers to internal and external rotation of the arm
Axial view	Overhead view; looking down onto
Cadaveric	A part derived from a dead body, or cadaver, intended for dissection and research use
Caudal	Anatomic term referring to the undersurface of a structure
Conjoined tendon	Tendon arising from coracoid process – consists of short head of biceps and coracobrachialis

Creep	Soft tissue elongation or deformation in response to a constant stress
Distal	Describes the spatial relationship of the part in question being further from the trunk
Drawer test	Clinical test to determine anterior shoulder laxity by passively extending the arm while it is abducted and externally rotated
Eccentric contraction	Type of contraction of the muscle where it elongates under tension in response to an external force (<i>i.e.</i> slow lowering of a weight)
External Rotation	Physiologic motion that involves rotating the part in question away from the midline of the body
Internal Rotation	Physiologic motion that involves rotating the part in question towards the midline of the body
Lateral	Describes the spatial relationship of the part in question being further away from the midline in the coronal plane
Medial	Describes the spatial relationship of the part in question being closer to the midline in the coronal plane
Osteotomy	Surgical cutting of bone or the removal of a piece of bone
Proximal	Describes the spatial relationship of the part in question being closer to the trunk
Retroversion	Anatomical reference of something being tipped backward
Stiffness	Applied force or moment needed to produce a unit of deformation of the construct under load (measured here in N/mm)
Transepicondylar axis	Line running from the medial to lateral epicondyle creating a plane of reference

Appendix B: Abbreviations List

Abd	Position of Abduction (see definitions)
Add	Position of Adduction (see definitions)
AC joint	Acromioclavicular joint
CAL	Coracoacromial ligament
CHL	Coracohumeral ligament
CT scan	Computerized tomography scan
DOF	Degrees of freedom
ER	External rotation
GHL	Glenohumeral ligament
GSA	George S. Athwal
HS defect	Hill-Sachs defect
IR	Internal Rotation
LTO	Lesser tuberosity osteotomy
NR	Neutral Rotation
RM-ANOVA	Repeated measures – Analysis of Variance test
ROM	Range of motion
SC joint	Sternoclavicular joint

Appendix C: Copyright Permissions

C1 – Co-author permission for “Bristow versus Latarjet Coracoid Transfer for Recurrent Instability with Glenoid Deficiency”

Hi Ryan,

I give you permission to use a version of our Bristow Latarjet article in your thesis.

Good luck with submitting,

Josh Giles, BESC

Ph.D. Candidate, University of Western Ontario

Research Engineer - Bioengineering Research Laboratory

Hand and Upper Limb Centre, St. Joseph's Health Centre

C2 – Copyright permission for “A Biomechanical Assessment of Superior Shoulder Translation after Reconstruction for Anterior Glenoid Bone Loss: The Latarjet Procedure versus Allograft Reconstruction”

Hi Ryan,

You can use it for academic purpose with no direct or in direct commercial use.

Regards,

Kaushik Shah

Sr. Re-prints and Licensing Sales Manager

Medknow Publications and Media Pvt. Ltd.

C3 – Copyright permission for use of images from Primal Pictures Ltd.



13 July 2013

To whom it may concern:

I can confirm that Ryan Degen, M.D. has formal permission from Primal Pictures to use images from Primal Pictures' 3D anatomy software for the following purpose:

To use our 3D shoulder model images for his introductory chapter of his thesis.

Samantha Barrow, Marketing Manager
for and on behalf of Primal Pictures Limited

Curriculum Vitae

Ryan Michael Degen

Department of Surgery, Division of Orthopedic Surgery

Schulich School of Medicine And Dentistry

Western University,

London, Ontario

Education

M.Sc. Candidate	Medical Biophysics Graduate Student (Masters Candidate), University of Western Ontario	Sept 2012 – Present
MD	Doctorate of Medicine, Michael G. DeGroot School of Medicine, McMaster University, Hamilton, Ontario.	Aug 2006 – May 2009
B.Sc.	Bachelor of Science (Biology), University of Western Ontario. London, Ontario	Aug 2003 – April 2006

Post-Graduate Education/Training

Orthopedic Surgery Residency, University of Western Ontario	July 2009 – Present
---	---------------------

Medical Licensures

College of Physicians and Surgeons of Ontario	July 2009 – Present
Canadian Medical Protective Association	July 2009 – Present

Professional Society Memberships

Canadian Orthopedic Association	July 2009 – Present
Canadian Medical Association	Aug 2006 – Present
Ontario Medical Association	Aug 2006 - Present

Honors and Awards

- Best Basic Science Paper; 40th Annual Orthopedic Resident's Day, Western University, London, Ont. Oct 2012
- Best Resident/Fellow Research Paper; Robert Zhong Department of Surgery Research Day, Western University, London, Ont. June 2013

Administrative Service

- Interviewer for CaRMs applicants for Orthopedic Residency Program, University of Western Ontario Jan 2011
- Host for interviewees for medical school interviews, McMaster University Mar 2007
- Reviewer for medical school applications, McMaster University Feb 2007

Publications

- 1) Hoppe DJ, **Degen R**, Bhandari M. Users' Guide to a Prognostic Study on an Orthopaedic Implant. Journal of Long-term Effects of Medical Implants. 2007; 17(2) pg. 135-144 Oct 2007
- 2) **Degen RM**, Hodgins JL, Bhandari M. The language of evidence based medicine: answers to common questions. Indian Journal of Orthopedics. 2008; 42 pg. 111-117 July 2008
- 3) **Degen RM**, Hoppe DJ, Petrisor BA, Bhandari M. Making Decisions about prognosis in evidence-based practice. Hand Clinics. 2009; 25(1) pg. 59-66 Feb 2009
- 4) **Degen RM**, Davey JR, Davey JR, Howard JL, McCalden RW, Naudie DD. Treatment of Periprosthetic Hip Infections with the Exactech Spacer Mold. Clin Orthop Relat Res, 2012, Oct; 470 (10): 2724-2729. Apr 2012
- 5) **Degen RM**, Giles JW, Boons HW, Litchfield RB, Johnson JA, Athwal GS. A Biomechanical Assessment of Superior Shoulder Translation after Reconstruction of Anterior Glenoid Bone Loss: The Latarjet Procedure versus Allograft Reconstruction. Int J Shoulder Surg, 2013. 7(1) 7-14. Mar 2013

- 6) **Degen RM**, Giles JW, Thompson SR, Litchfield RB, Athwal GS. Biomechanics of Complex Shoulder Instability. Clin Sports Med, 2013. April 2013

Podium Presentations

- Degen RM**, Davey JR, Howard JL, Bourne RB, McCalden RW, Naudie DN. Outcomes of pre-formed gentamicin impregnated spacers in the treatment of deep periprosthetic infections of the hip. 38th Annual UWO Orthopedic Resident's Research Day. London, ON Oct 2010
- Degen RM**, Davey JR, Howard JL, Bourne RB, McCalden RW, Naudie DN. Treatment of Periprosthetic Hip Infections with the Exactech Spacer Mold. Podium Presentation. Musculoskeletal Infectious Society, 21st Annual Open Scientific Meeting, Mayo Clinic, Rochester, MN Aug 2011
- Degen RM**, MacDermid JC, Roth J, Grewal R, Drosdowech D, Faber KJ, Athwal GS. Prevalence of Symptoms of Depression, Panic Disorder, and PTSD in an Injured Worker Upper Extremity Clinic. 39th Annual UWO Orthopedic Resident's Research Day, London, ON Sept 2011
- Degen RM**, MacDermid JC, Roth J, Grewal R, Drosdowech D, Faber KJ, Athwal GS. Prevalence of Symptoms of Depression, Panic Disorder, and PTSD in an Injured Worker Upper Extremity Clinic. Canadian Orthopedic Association General Meeting, Ottawa ON June 2012
- Puskas G**, Giles JW, Welsh M, Degen RM, Johnson JA, Athwal GA, Strength of Allograft Reconstruction for Hill-Sachs Defects: A Biomechanical Comparison of Two Fixation Techniques. Swiss Orthopedic Conference (Jareskongress der Schweizerischen Gessellschaft fur Orthopadie und Traumatologie) Basel, Switzerland. June 2012
- Degen RM**, Giles JW, Johnson JA, Athwal GS. The Bristow-Latarjet: Why These Procedures Should Not Be Considered Synonymous. Resident's Research Day, University of Western Ontario, London, ON. Winner of Basic Science Category. Oct 2012

- Giles JW, Degen RM, Johnson JA, Athwal GS.** The Bristow-Latarjet: Why These Procedures Should Not Be Considered Synonymous. Canadian Orthopedic Association General Meeting, Winnipeg, ON June 2013
- Degen RM, Giles JG, Johnson JA, Athwal GS.** The Bristow-Latarjet Coracoid Transfer for Managing Recurrent Shoulder Instability: Why These Procedures Should Not Be Considered Synonymous. Robert Zhong Department of Surgery Research Day, London, ON. Winner of Resident/Fellow Category. June 2013

Poster Presentations

- Degen RM, Davey JR, Howard JL, Bourne RB, McCalden RW, Naudie DN.** The use of a gentamicin impregnated articulating spacer for the treatment of deep periprosthetic hip infections. Canadian Orthopedic Association annual meeting, Halifax, NS July 2011
- Puskas G, Giles JW, Welsh M, Degen RM, Johnson JA, Athwal GA.** Humeral Head Allograft Fixation for Reconstruction of Hill-Sachs Defects: Antegrade versus Retrograde Fixation? Canadian Orthopedic Association General Meeting, Winnipeg, ON June 2013
- Degen RM, Giles JW, Boons HW, Litchfield RB, Johnson JA, Athwal GS.** A Biomechanical Assessment of Superior Shoulder Translation after Reconstruction of Anterior Glenoid Bone Loss: The Latarjet Procedure versus Allograft Reconstruction. Canadian Orthopedic Association General Meeting, Winnipeg, ON June 2013
- Degen RM, Giles JW, Johnson JA, Athwal GS.** Comparing Remplissage with Latarjet Coracoid Transfer for Recurrent Shoulder Instability with a Hill-Sachs Defect: An Engaging Topic. Canadian Orthopedic Association General Meeting, Winnipeg, ON June 2013

Research Experience

- Research Assistant, Fowler Kennedy Sports Medicine Clinic, University of Western Ontario, University Hospital, London, ON Jan 2002 – Aug 2006

3rd year Research block, Hand and Upper Limb – Biomechanics Lab, St. Joseph's Hospital, London, ON Oct 2011 – Jan 2012

Professional Development

AO North America, Continuing Medical Education; Principles of Fracture Management, Basic Course, Toronto, ON Nov 2010

AAHKS 3rd Resident Course and 21st Annual Meeting, Dallas, TX Nov 2011

Medical Biophysics Scientific Communication Course – UWO, London ON Mar 2012

Canadian Orthopedic Association Annual Meeting – Ottawa, ON June 2012

American Academy of Orthopedic Surgeons Annual Meeting – Chicago, Illinois Mar 2013

Resident Leadership Forum, American Orthopedic Association Annual Meeting – Denver, Colorado June 2013